

Corneal Iron Ring After Conductive Keratoplasty

George D. Kymionis, MD, PhD,
Tatiana L. Naoumidi, MD,
Ioannis M. Aslanides, MD, PhD, and
Ioannis G. Pallikaris, MD, PhD

PURPOSE: To report formation of corneal iron ring deposits after conductive keratoplasty.

DESIGN: Observational case report.

METHODS: Case report.

RESULTS: A 54-year-old woman underwent conductive keratoplasty for hyperopia. One year after conductive keratoplasty, iron ring pattern pigmentation was detected at the corneal epithelium of both eyes.

CONCLUSIONS: This is the first report of the appearance of corneal iron ring deposits following conductive keratoplasty treatment in a patient. It is suggested that alterations in tear film stability, resulting from conductive keratoplasty-induced changes in corneal curvature, constitute the contributory factor for these deposits. (Am J Ophthalmol 2003;136:378–379. © 2003 by Elsevier Inc. All rights reserved.)

IRON CORNEAL DEPOSITS ARE LOCATED IN THE BASAL corneal epithelium and have been reported to occur after several refractive corneal procedures.^{1,2} Furthermore, iron lines have been associated with corneal pathology, such as corneal scars and pterygium.³ Several theories regarding the origin of iron corneal deposits have been postulated, with the most favorable being suggesting that they are formed in places where the cornea allows accumulation of tears.³

Recently, a new method called conductive keratoplasty (CK; Refractec Inc., Irvine, California, USA) has been used for the correction of low to moderate hyperopia with promising results.^{4–6} The concept of this minimally invasive hyperopic correction approach is to increase the curvature of the central cornea (and thereby correct hyperopic refractive error) by thermokeratoplasty collagen contraction into the peripheral cornea after the insertion of a keratoplasty tip of 450 μm . To our knowledge, there are no reports of corneal iron deposits after CK.

Accepted for publication Feb 12, 2003.

From the Department of Ophthalmology (G.D.K., I.G.P.) and the Vardinoyannion Eye Institute of Crete (G.D.K., T.L.N., I.M.A., I.G.P.), University of Crete, Heraklion, Crete, Greece.

Inquiries to George D. Kymionis, MD, PhD, Department of Ophthalmology, University Of Crete, VEIC, Medical School, 71110 Heraklion, Crete, Greece; Fax: (+30) 2810-394653; e-mail: kymionis@med.uoc.gr

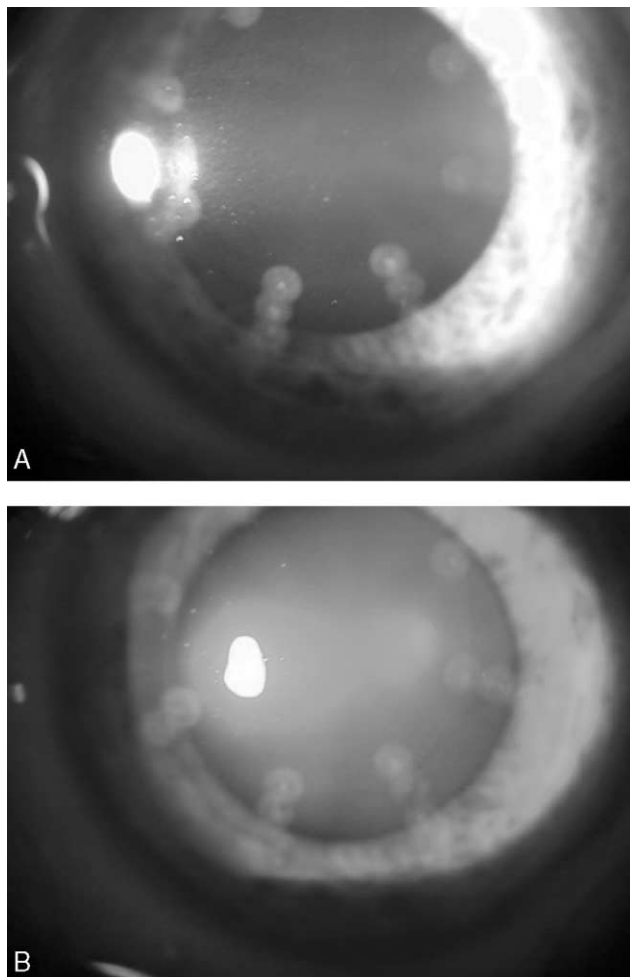


FIGURE 1. Slit-lamp photographs (A and B) reveal the peripheral epithelial iron ring between the conductive keratoplasty-treated spots.

In this case report, we describe corneal iron ring deposits in a 54-year-old woman who underwent a CK procedure for hyperopia. Manifest refraction was $+3.00/-0.75 \times 180$ degrees in the right (OD) and $+3.00/-0.75 \times 010$ degrees in the left eye (OS). Uncorrected visual acuity (UCVA) was ODS: 20/50, whereas best-corrected visual acuity (BCVA) was 20/20 in both eyes. Preoperative examination was normal with no contraindications to CK. Corneal topography simulated K-values were $40.79/42.35 \times 088$ degrees in the right eye and $40.91/42.37 \times 090$ degrees in the left.

The patient was informed about the possible intraoperative and postoperative complications and the possibilities of favorable outcome and was included in a prospective clinical study investigating the safety and efficacy of the CK as a refractive treatment in hyperopic patients. In parallel, the patient gave written informed consent in

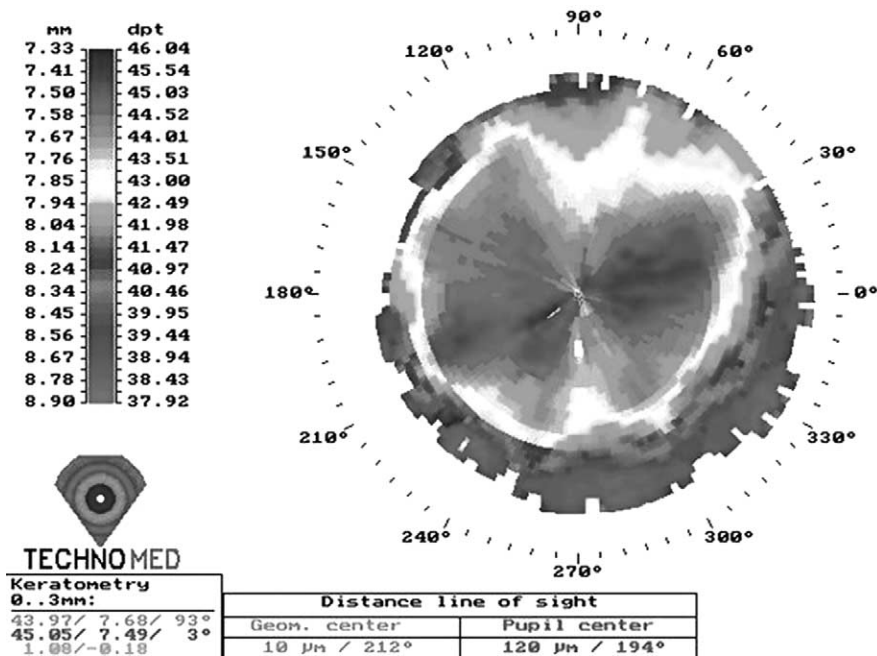


FIGURE 2. Topography after conductive keratoplasty demonstrates the correlation between the iron ring and the base of increasing corneal curvature.

accordance with institutional guidelines and the Declaration of Helsinki.

Eight spots at each of the 6-, 7-, and 8-mm optical zone (24 spots in total) were performed for hyperopic component correction on both eyes, while four additional spots (at 8-mm optical zone) were done at the place of topographically flatter astigmatic axis (two at each side) in both eyes (OD at 180 degrees and OS at 010 degrees). Before the CK procedure, central (OD: 536/OS: 535 μm) and peripheral pachymetric measurements (ultrasonic pachymetry, DGH 5100 Technology, Inc, Cleveland, Ohio, USA) were taken. The procedure was completed without any complications. Postoperatively, the patient was instructed to use dexamethasone (Maxidex; Alcon Laboratories, Fort Worth, Texas, USA) and ofloxacin 0.3% drops four times a day for 7 days.

After 1 year, the patient's UCVA and BCVA were 20/25 and 20/20 in both eyes, respectively, while manifest refraction was OD: +0.75/-0.50 × 120 degrees/OS: +0.50/-0.75 × 090 degrees. Slit-lamp examination revealed a moderately dense yellow-brown line on both corneas (Figure 1, A and B). The diameter of the pigmentation ring was 6.5-mm with a 0.5-mm width and was more pronounced at the inferotemporal part of the cornea. In addition, the location of the iron line was correlated with the base of the topographic optical zone (TechnoMed C-Scan/Technomed GmbH, Baesweiler, Germany; Figure 2).

Corneal iron lines have been described in several pathologic conditions as well as following corneal refractive surgery. In the present case report, we describe a partially brown-colored corneal iron ring, located in between the CK-treated spots observed in a patient who had undergone CK treatment. It is believed that the formation of such a deposit is due to alterations in tear film stability caused by CK-induced changes in corneal curvature.

REFERENCES

1. Vongthongsri A, Chuck RS, Pepose JS. Corneal iron deposits after laser in situ keratomileusis. *Am J Ophthalmol* 1999;127: 85-86.
2. Probst LE, Almasswary MA, Bell J. Pseudo-Fleisher ring after hyperopic laser in situ keratomileusis. *J Cataract Refract Surg* 1999;25:868-870.
3. Gass JDM. The iron lines of the superficial cornea: Hudson-Stahli line, Stocker's line and Fleisher's ring. *Arch Ophthalmol* 1964;71:348-358.
4. Asbell PA, Maloney RK, Davidorf J, et al. Conductive keratoplasty for the correction of hyperopia. *Trans Am Ophthalmol Soc* 2001;99:79-87.
5. McDonald MB, Davidorf J, Maloney RK, Manche EE, Hersh P. Conductive keratoplasty for the correction of low to moderate hyperopia. *Ophthalmology* 2002;109:637-649.
6. McDonald MB, Hersh P, Manche EE, et al. Conductive keratoplasty for the correction of low to moderate hyperopia: U.S. clinical trial 1-year results on 355 eyes. *Ophthalmology* 2002;109:1978-1989.