
Corneal perforation after conductive keratoplasty with previous refractive surgery

George D. Kymionis, MD, PhD, Patrik Titze, MD, Marinos M. Markomanolakis, MD, Ioannis M. Aslanides, MD, PhD, Ioannis G. Pallikaris, MD, PhD

A 56-year-old woman had conductive keratoplasty (CK) for residual hyperopia and astigmatism. Three years before the procedure, the patient had arcuate keratotomy, followed by laser in situ keratomileusis 2 years later for high astigmatism correction in both eyes. During CK, a corneal perforation occurred in the right eye; during the postoperative examination, an iris perforation and anterior subcapsule opacification were seen beneath the perforation site. The perforation was managed with a bandage contact lens and an antibiotic-steroid ointment; it had a negative Seidel sign by the third day. The surgery in the left eye was uneventful. Three months after the procedure, the uncorrected visual acuity was 20/32 and the best corrected visual acuity 20/20 in both eyes with a significant improvement in corneal topography. Care must be taken to prevent CK-treated spots from coinciding with areas in the corneal stroma that might have been altered by previous refractive procedures.

J Cataract Refract Surg 2003; 29:2452-2454 © 2003 ASCRS and ESCRS

Hyperopia is one of the most challenging areas of refractive surgery. Conductive keratoplasty (CK) has been used for the past few years to correct low to moderate hyperopia with promising results.¹⁻³ A keratoplasty tip of 450 μm is inserted directly in the peripheral cornea at the 6.0 mm, 7.0 mm, and 8.0 mm treatment zones, delivering radio frequencies (350 kHz). The postthermokeratoplasty collagen contraction at CK-treated spots increases the curvature of the central cornea and decreases hyperopia.

Preliminary results have demonstrated that CK is a safe and predictable method for the correction of low to moderate hyperopia.¹⁻³ The application of CK as an enhancement procedure for the correction of residual

hyperopia and astigmatism after previous refractive procedures is under investigation.

We present a case in which a corneal and iris perforation expanded to the anterior capsule after CK in a patient with a previous refractive procedure (combined arcuate cut and laser in situ keratomileusis [LASIK]).

Case Report

A healthy 53-year-old woman was referred for the correction of astigmatism. The manifest refraction was +0.75 -3.50×15 in the right eye and +1.00 -3.25×10 in the left eye. The uncorrected visual acuity (UCVA) was 20/50 in the right eye and 20/40 in the left eye, and the best corrected visual acuity (BCVA) was 20/20 in both eyes.

In 1999, arcuate keratotomy (AK) was performed in both eyes for the correction of astigmatism (right eye: 1 incision, 90 degrees to 135 degrees at 580 μm ; left eye: 1 incision, 90 degrees to 135 degrees at 600 μm). The incision was 45 degrees in 90% of the thinnest part of the cornea at the incision location, and the optical zone was 6.0 mm. There were no intraoperative or postoperative complications.

Two years postoperatively, the patient's refraction was $-0.50 -2.25 \times 155$ in the right eye and $+0.50 -2.75 \times 150$ in the left eye. The UCVA was 20/40 and the BCVA 20/20 in both eyes. The central pachymetry was 545 μm in the right eye and 533 μm in the left eye. Laser in situ

Accepted for publication March 24, 2003.

From the Department of Ophthalmology, Vardinoyannion Eye Institute of Crete, University of Crete, Heraklion, Greece.

None of the authors has a financial or proprietary interest in any material or method mentioned.

Reprint requests to George D. Kymionis, MD, PhD, Vardinoyannion Eye Institute of Crete, Medical School, University Of Crete, 71110 Heraklion, Crete, Greece. E-mail: kymionis@med.uoc.gr.

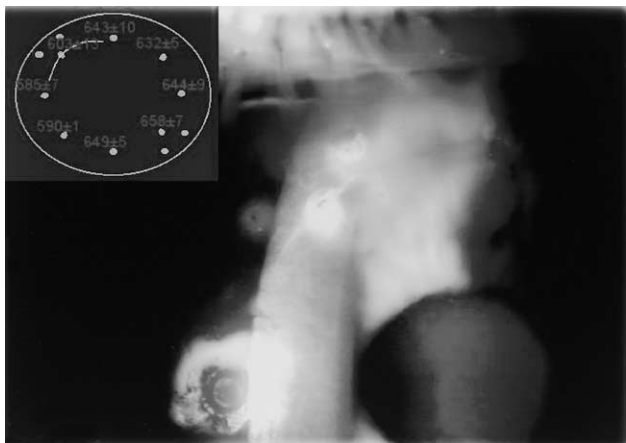

Figure 1. (Kymionis) Slitlamp photograph at the CK-treated spot (within the groove of the previous AK incision) with corneal perforation. Number, location, and pachymetric measurements (mean \pm SD) of CK-treated spots in correlation with the previous AK incision are indicated (top left).

keratomileusis was performed to correct the residual astigmatism using the automated Summit Krumeich-Barraquer microkeratome (Alcon) with a 130 μ m plate and the Aesculap-Meditec MEL 70 excimer laser. The procedure was uneventful, and no intraoperative or postoperative complications related to the previous AK incision or LASIK were observed.

In September 2002, the patient's refraction was $+1.50 -0.75 \times 140$ in the right eye and $+1.50 -1.00 \times 130$ in the left eye. The UCVA was 20/40 in the right eye and 20/32 in the left eye; the BCVA was 20/20 in both eyes. The patient wanted to correct the residual refractive error. She was informed of the possible intraoperative and postoperative complications and the possibility of a positive outcome. She was included in a prospective clinical study for the safety and efficacy of CK as an enhancement procedure in patients with previous refractive surgery and gave written informed consent in accordance with the Declaration of Helsinki.

Eight spots were performed at the 7.0 mm optical zone for hyperopic correction in the right eye, and 4 additional spots were made at the 8.0 mm optical zone at the topographically flatter axis of astigmatism (2 in each side) in both eyes (Figure 1). Before the CK procedure, peripheral pachymetry measurements (ultrasound pachymetry, DGH 5100, DGH Technology, Inc.) (5 measurements) were made at the 6.0 mm and 7.0 mm optical zones and at the site of the previous AK. No pachymetry measurement was less than 560 μ m.

During the right-eye procedure, corneal penetration and aqueous leakage were observed in the CK-treated spot, which was within the groove of the previous AK incision. After the operation, a bandage contact lens was fitted and an antibiotic-steroid combination eye ointment 4 times a day was

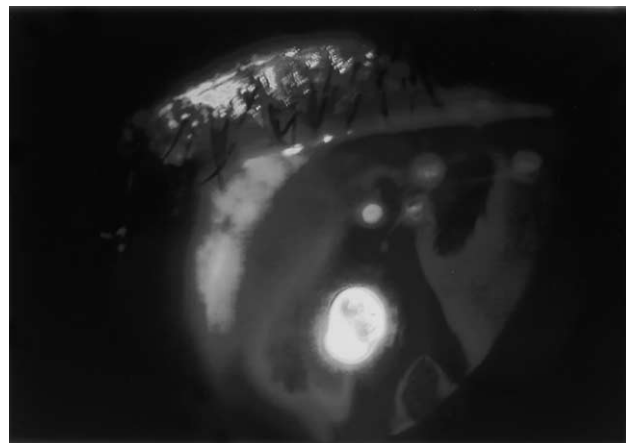


Figure 2. (Kymionis) Slitlamp photograph with retroillumination shows iris perforation.

prescribed. The next day, aqueous leakage continued from the site of the corneal perforation (positive Seidel sign). Slitlamp examination with retroillumination revealed an iris perforation (Figure 2). After iris dilation, an area of anterior capsule opacification (ACO) was found beneath the iris transillumination defect (Figure 3). Three days postoperatively, the corneal perforation was healed; UCVA was 20/25 in both eyes with significant corneal topographic improvement.

After 3 months, the UCVA was 20/25 and the BCVA was 20/20 in both eyes; the manifest refraction was -0.75×145 in the right eye and $+0.50 -0.75 \times 160$ in the left

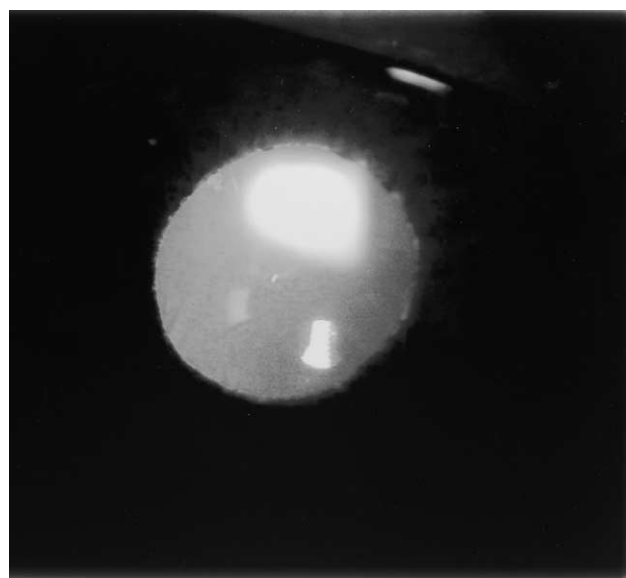

Figure 3. (Kymionis) Slitlamp photograph shows the area of ACO.

eye with a significant improvement in corneal topography. No change in lens opacification was observed, and the patient was satisfied with the outcome.

Discussion

Combined procedures in patients with high astigmatic errors have been performed to achieve an additive refractive effect (eg, astigmatic keratotomy and LASIK).⁴ The major limitation in combined techniques is lower predictability than in first-time procedures. For this reason, a residual refractive error is frequently presented and in some cases, an additional refractive procedure is needed. As the preliminary results of CK are encouraging and the technique is minimally invasive, use of it as an enhancement procedure to correct low hyperopic refractive errors and hyperopic astigmatism in patients with previous refractive procedures appears promising.

In our patient, the final refractive outcome in both eyes was successful but the intraoperative corneal perforation was a serious complication that could be vision threatening. There are several possible reasons for the corneal penetration. The most probable is that the corneal scar formation after AK reacted to the thermal effect or was less rigid and mechanically weakened than the virgin collagen, resulting in reopening of the AK (Figure 1). Another possible explanation is that the cornea was thinned in the part of the previous AK incision. Although there were no suspicious findings when we performed peripheral corneal pachymetry, the head of the probe in ultrasonic pachymetry could not

have detected small parts of the cornea that had been thinned by the previous AK incision and were therefore prone to perforation. Additionally, a thicker amount of epithelial tissue might have been present within the most superficial part of the AK incision as part of the healing process, which would allow deeper penetration of the CK probe than in the adjacent, unoperated corneal stroma.

Conductive keratoplasty may represent an alternative treatment for residual refractive errors in patients with previous refractive procedures, but special care must be taken to prevent the CK-treated spots from coinciding with areas in the corneal stroma that might have been altered by previous refractive procedures (eg, incisional surgery).

References

1. Mendez GA, Mendez Noble A. Conductive keratoplasty for the correction of hyperopia. In: Sher NA, ed, *Surgery for Hyperopia and Presbyopia*. Philadelphia, PA, Williams & Wilkins, 1997; 163–171
2. Asbell PA, Maloney RK, Davidorf J, et al. Conductive keratoplasty for the correction of hyperopia. *Trans Am Ophthalmol Soc* 2001; 99:79–84; discussion, 84–87
3. McDonald MB, Davidorf J, Maloney RK, et al. Conductive keratoplasty for the correction of low to moderate hyperopia; 1-year results on the first 54 eyes. *Ophthalmology* 2002; 109:637–649; discussion by CL Blanton, 649–650; correction, 1583
4. Manche EE, Maloney RK. Astigmatic keratotomy combined with myopic keratomileusis in situ for compound myopic astigmatism. *Am J Ophthalmol* 1996; 122:18–28