

# Efficacy of 2 types of silicone hydrogel bandage contact lenses after photorefractive keratectomy

Michael A. Grentzelos, MD, Sotiris Plainis, MSc, PhD, Nikolaos I. Astyrakakis, OD, Vasilios F. Diakonis, MD, George D. Kymionis, MD, PhD, Panagiotis Kallinikos, PhD, Ioannis G. Pallikaris, MD, PhD

**PURPOSE:** To compare the efficacy of 2 types of silicone hydrogel bandage contact lenses with high oxygen transmissibility after photorefractive keratectomy (PRK).

**SETTING:** Institute of Vision and Optics, Faculty of Medicine, University of Crete, Heraklion, Crete, Greece.

**METHODS:** In this prospective study, 1 eye of patients having bilateral PRK was randomly fitted with a bandage contact lens of lotrafilcon A (Night & Day) and the fellow eye, with a bandage contact lens of lotrafilcon B (O<sub>2</sub>Optix). The patients and the examiner were masked to which bandage contact lens type was in which eye. Patients were examined on the day of surgery and 1, 3, and 5 days postoperatively. Postoperative examinations included uncorrected distance visual acuity and slitlamp biomicroscopy to assess epithelial defect size. Subjective evaluation of pain and vision was recorded 1, 2, 3, and 4 days postoperatively.

**RESULTS:** The study enrolled 44 patients (88 eyes). The mean epithelial defect size immediately after surgery was 47.0 mm<sup>2</sup> with both types of bandage contact lenses. There was no statistically significant difference in epithelial defect size between the 2 lenses at any postoperative visit. Three days postoperatively, reepithelialization was complete in 75.0% of eyes in the lotrafilcon A group and 72.7% of the eyes in the lotrafilcon B group.

**CONCLUSION:** There were no differences in corneal reepithelialization or subjective measurements after PRK between the 2 types of silicone hydrogel bandage contact lenses.

*J Cataract Refract Surg 2009; 35:2103–2108 © 2009 ASCRS and ESCRS*

Although laser in situ keratomileusis (LASIK) is the most popular refractive procedure today, photorefractive keratectomy (PRK) is an older, well-established flapless procedure that has been performed for more than 20 years.<sup>1</sup> However, eyes with PRK have more postoperative pain than eyes that have had LASIK as well as delayed visual recovery.<sup>2</sup> It is also well established that soft contact lenses can be used as a bandage after PRK or laser-assisted subepithelial keratectomy (LASEK).<sup>3–5</sup> This treatment was initially used to reduce postoperative pain.<sup>6,7</sup> However, subsequent studies found that application of a bandage contact lens increased the time and quality of epithelial healing and preserved the epithelial flap after LASIK.<sup>8–10</sup>

To achieve optimum biocompatibility for overnight wear, bandage contact lenses should allow enough oxygen flow to maintain corneal aerobic metabolism. Silicone hydrogel contact lenses use materials with high oxygen permeability and thus meet this need.<sup>11</sup> Even so, conventional contact lenses from hydrogel

materials remain the most common type of bandage contact lens after corneal refractive surgery; however, because of their low oxygen transmissibility, they do not meet the criterion for overnight wear. Recent studies<sup>9,10</sup> report that in most patients, silicone hydrogel contact lenses of lotrafilcon A provide significantly faster corneal reepithelialization and reduced patient discomfort after PRK. This lens (Night & Day, Ciba Vision) received U.S. Food and Drug Administration (FDA) approval for 30 days of continuous wear and for use as a bandage contact lens for therapeutic applications.<sup>12</sup>

During the past 5 years, other contact lenses of newer silicone hydrogel materials, such as lotrafilcon B, have been introduced on the market. Although the lotrafilcon B lens (O<sub>2</sub>Optix, Ciba Vision) received FDA approval for 6 days of continuous wear, a period satisfying a criterion for epithelial healing, it has not been approved for use as a bandage lens for therapeutic purposes.

The aim of the current study was to compare the post-PRK performance of lotrafilcon A and lotrafilcon B hydrogel contact lenses from the same manufacturer. Outcome measures were postoperative vision, pain, epithelial defect size, and speed of reepithelialization.

## PATIENTS AND METHODS

This prospective double-masked comparative clinical study enrolled patients who had bilateral PRK for the correction of myopia at the Institute of Vision and Optics, University of Crete. All patients provided written consent before enrollment. The research conformed to the tenets of the Declaration of Helsinki and followed a protocol approved by the University of Crete Research Board.

Exclusion criteria included previous refractive surgery, myopic refractive error higher than 8.00 diopters (D), anisometropia higher than 2.00 D, and ocular or systemic disease that could affect epithelial healing. All patients were asked to cease contact lens wear at least 3 weeks before the preoperative examination.

## Surgical Technique

The surgical procedure was performed under sterile conditions using topical anesthesia of proxymetacaine hydrochloride 0.5% eyedrops. The epithelium was removed with a soft rotating brush. Stromal ablation was performed with a 400 Hz Allegretto laser platform (WaveLight AG). After ablation, mitomycin-C 0.02% was applied for up to 15 seconds. At the end of the procedure, 1 eye of each patient, randomly determined by a coin flip, was fitted with a lotrafilcon A bandage contact lens (Night & Day) and the fellow eye, with a lotrafilcon B bandage contact lens (O<sub>2</sub>Optix). Table 1 shows the specifications of the lenses. Patients were masked to which type of bandage contact lens was in which eye. The same clinician evaluated the fit of the bandage contact lenses using slitlamp biomicroscopy.

The postoperative medication regimen was the same for both eyes and included diclofenac sodium 0.1% for 2 days and tobramycin-dexamethasone drops until the bandage contact lens was removed. Patients were encouraged to use artificial tears every 30 minutes until the day of complete

**Table 1.** Contact lens characteristics.

Parameter	Bandage Contact Lens	
	Night & Day	O <sub>2</sub> Optix
Material		
Name	Lotrafilcon A	Lotrafilcon B
Type	Silicone hydrogel	Silicone hydrogel
Dk/t	140	110
Water content (%)	24	33
Diameter (mm)	13.8	14.2
Back vertex	Plano	Plano
power (D)		
Back optic	8.40	8.60
zone radius (mm)		

Dk/t = oxygen transmissibility coefficient

reepithelialization. For pain control, patients could take 1 to 2 tablets of oral nimesulide 100 mg.

## Postoperative Follow-up

All patients were examined 1, 3, and 5 days postoperatively. Each postoperative examination included slitlamp biomicroscopy and assessment of uncorrected distance visual acuity measured using logMAR ETDRS charts at 4 m. Slitlamp biomicroscopy was used to evaluate the integrity of the corneal media and objectively assess epithelial healing. An ophthalmologist who was unaware of the type of bandage contact lens in each eye performed the assessments. The epithelial defect size was calculated from the remaining area (A) of the epithelial defects using the following equation:

$$A = \pi[(a+b)/4]^2$$

where *a* is the shortest dimension of the defect and *b* is the longest dimension. Other researchers have used this equation to determine the remaining epithelial defect size after PRK.<sup>10</sup> Each bandage contact lens was removed when there was no observable remaining epithelial defect. After removal of the bandage contact lens, fluorescein was instilled to confirm the absence of an epithelial defect. The day of epithelial healing was recorded in each case.

Subjective evaluation of pain (discomfort) and vision was also recorded on every postoperative day. Pain scores were evaluated on a scale of 0 to 4 as follows: 0 = no discomfort or pain; 1 = mild discomfort; 2 = moderate burning pain; 3 = burning pain requiring oral medication (nimesulide 100 mg); 4 = severe constant or sharp pain not mitigated with oral medication. Vision scores were evaluated on a scale of 0 to 4, with 0 representing blurred vision and 4, vision simulating the patient's corrected distance visual acuity.

## Statistical Analysis

Based on pilot data and previously published studies,<sup>10</sup> the maximum standard deviation of the difference in epithelial defect size between the lotrafilcon A contact lens and the lotrafilcon B contact lens 1 day and 3 days postoperatively is  $\pm 5$ . Thus, using a sample size of 40, the study was designed to detect a difference in epithelial defect size of 2.3 with 80%

Submitted: February 26, 2009.

Final revision submitted: June 23, 2009.

Accepted: July 18, 2009.

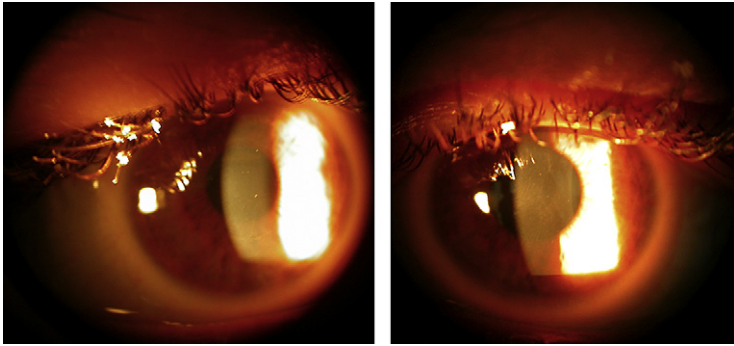
From the Institute of Vision and Optics, Faculty of Medicine, University of Crete, Crete, Greece.

No author has a financial or proprietary interest in any material or method mentioned.

Presented in part at the annual meeting of the American Academy of Optometry, Anaheim, California, USA, October 2008.

Joanna Moschandreas helped in the statistical design of the study. AMVIS Hellas SA, Athens, Greece, supplied the contact lenses.

Corresponding author: Michael A. Grentzelos, MD, University of Crete, Faculty of Medicine, Institute of Vision and Optics (IVO), 71003, Heraklion, Crete, Greece. E-mail: [mgrentz@gmail.com](mailto:mgrentz@gmail.com).



**Figure 1.** Slitlamp biomicroscopic images of the same eye at day 1 (*left*) and day 3 (*right*) postoperatively.

power at a significance level of 5%. This value corresponds to the average defect size 1 day before complete reepithelialization reported by Engle et al.<sup>10</sup>

Statistical analysis was performed using StatView software (version 5.0, SAS Institute, Inc.) on a Macintosh platform (Apple Inc.). Subjective and objective outcomes were compared using paired Student *t* and chi-square tests, where appropriate. Because the number of discordant pairs in each case was small (<10), paired proportions were compared using tests based on exact binomial probabilities.

## RESULTS

Forty-four patients (88 eyes) were enrolled the study. The mean age of the 22 men and 22 women was 28.5 years (range 20 to 45 years). Slitlamp biomicroscopy at the end of surgery showed the fit of the bandage contact lens was satisfactory in all eyes.

**Figure 1** shows characteristic slitlamp biomicroscopic images of the cornea in the same eye 1 day and 3 days postoperatively. The corneal epithelial defect was mostly healed by the third postoperative day.

The mean attempted spherical equivalent was  $-3.90 \text{ D} \pm 1.82 \text{ (SD)}$  in the lotrafilcon A group and  $-3.88 \pm 1.81 \text{ D}$  in the lotrafilcon B group; the difference was not statistically significant ( $P = .69$ ). The mean epithelial defect size immediately after surgery was  $47.0 \text{ mm}^2$  in both groups; the range of the defect was  $29.7$  to  $78.8 \text{ mm}^2$  in the lotrafilcon A group and  $31.2$  to  $70.8 \text{ mm}^2$  in the lotrafilcon B group. **Figure 2** shows the correlation for epithelial defect size between the 2 bandage contact lenses immediately after surgery.

On average, eyes in the lotrafilcon B group had slightly larger areas of epithelial defect than eyes in the lotrafilcon A group. The difference was not statistically significant at 1 day ( $26.0 \text{ mm}^2$  versus  $25.7 \text{ mm}^2$ ;  $P = .67$ ), 3 days ( $2.2 \text{ mm}^2$  versus  $1.9 \text{ mm}^2$ ;  $P = .64$ ), or 5 days ( $0.2 \text{ mm}^2$  versus  $0.3 \text{ mm}^2$ ;  $P = .56$ ) (**Figure 3**).

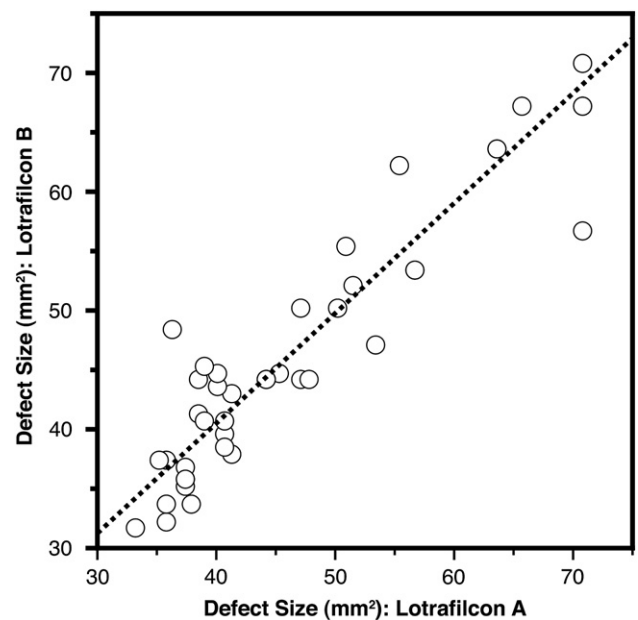
Three days postoperatively, reepithelialization was complete in 33 eyes (75.0%) in the lotrafilcon A group and 32 eyes (72.7%) in the lotrafilcon B group. At 5 days, reepithelialization was complete in 42 eyes (95.5%) and 41 eyes (93.2%), respectively. The

difference between groups was not statistically significant on either day ( $P = 1.00$ ).

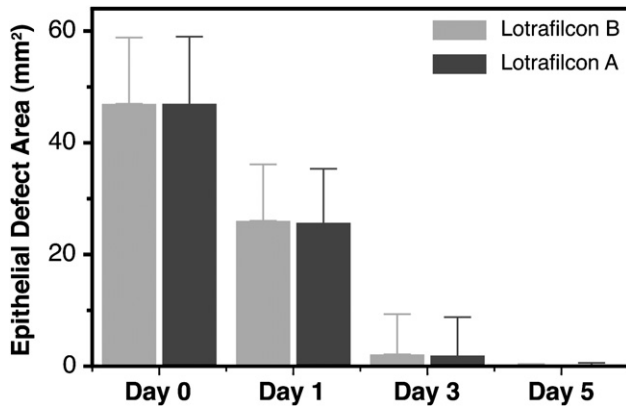
**Figure 4** compares the mean subjective pain and vision scores between the 2 groups at all time points. There were no statistically significant differences between the 2 bandage contact lenses at any time ( $P > .10$ ).

## DISCUSSION

Although the therapeutic use of soft contact lenses was reported almost 40 years ago,<sup>13-15</sup> their use has increased significantly in recent years as a result of the introduction of surgical techniques designed to permanently correct refractive errors. Soft contact lenses used as a bandage after refractive surgery aid in corneal protection and pain relief and accelerate the healing process<sup>16</sup> by preserving the epithelial flap after



**Figure 2.** Correlation of the area of epithelial defect between the 2 silicone hydrogel lenses immediately after surgery. The dashed line represents the least-square regression fit ( $r^2 = 0.94$ ).



**Figure 3.** Plot of the mean epithelial defect size on all postoperative days. The error bars represent  $\pm 1$  SD. Values at day 5 correspond to 11 eyes and 12 eyes (lotrafilcon A and lotrafilcon B, respectively) (Day 0 = day of surgery).

LASIK or by promoting reepithelialization after PRK or LASEK.<sup>5,9,10</sup>

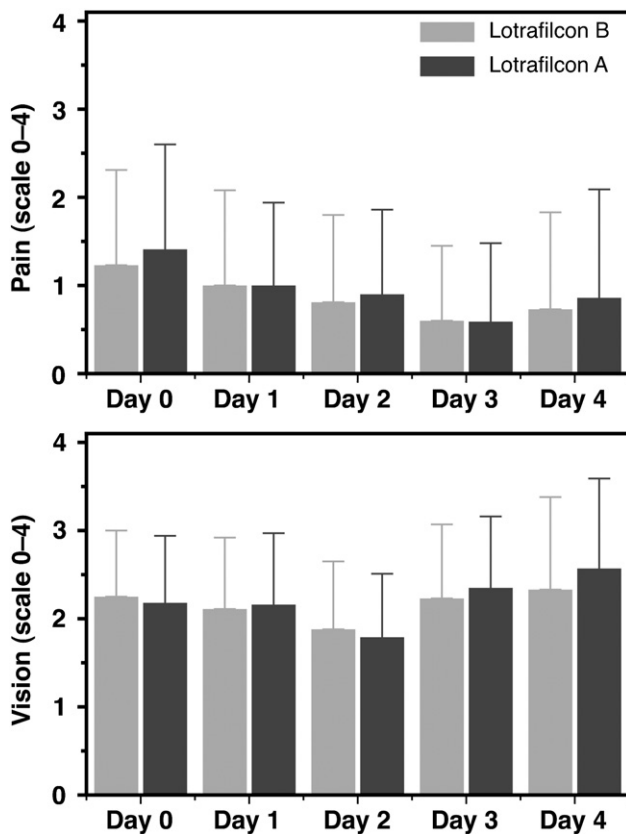
Contact lenses interact mechanically with the cornea and modify the physiologic processes of corneal tissue, reducing corneal function. The most frequent complications of contact lens wear are the direct result of

impaired oxygen supply to the cornea. Rigid gas-permeable and soft contact lens materials with high oxygen permeability have driven the success of continuous wear because they have eliminated the hypoxic effects previously associated with extended-wear lenses.<sup>17,18</sup> Essential to this was the establishment of corneal oxygen requirements and the development of materials and manufacturing techniques to meet those requirements. The introduction in the late 1990s of silicone hydrogel contact lenses designed for continuous wear was beneficial to the field of refractive surgery. The high oxygen transmissibility of these lenses alleviates hypoxic-induced complications, enhancing wound healing and epithelial cell reproduction after refractive surgery.

Photorefractive keratectomy, a well-established flapless refractive procedure, has been performed for more than 20 years.<sup>1</sup> However, significant drawbacks of PRK remain; that is, it causes greater postoperative pain and more delayed visual recovery than LASIK. The therapeutic value of the lotrafilcon A bandage contact lens has been shown,<sup>19</sup> as has its efficacy in achieving faster corneal reepithelialization and in reducing discomfort after PRK.<sup>10</sup> Therefore, we evaluated whether another silicone hydrogel bandage contact lens with different technical characteristics produced by the same manufacturer would have the same efficacy. Our hypothesis was that a bandage contact lens of lotrafilcon B, which has FDA approval for 6 days of continuous wear (versus 30 days for the lotrafilcon A lens), would be as efficacious as the lotrafilcon A lens in reepithelialization after PRK.

Recently, Gil-Cazorla et al.<sup>5</sup> evaluated the efficacy of 2 types of silicone hydrogel contact lenses used as a bandage after LASEK. The 2 lenses differed significantly in oxygen transmissibility, water content, surface treatment, and initial modulus. The authors found no significant differences between the 2 lenses in vision, corneal epithelial status, conjunctival and limbal hyperemia, or lens movement. However, the results are not directly comparable to those in our study because of the significant differences between LASEK and PRK.

The present study, in which each patient wore both types of lenses, was a direct comparison between lotrafilcon A and lotrafilcon B lens after PRK. We controlled factors that could influence the epithelial healing process, such as the environment and physiologic healing response, and patients and examiners were masked to which type of lens was in which eye. Although, on average, eyes with a lotrafilcon A lens had slightly smaller areas of epithelial defect than eyes with a lotrafilcon B lens, there were no statistically significant differences between the 2 lenses at any postoperative examination. There was also no difference in the number of



**Figure 4.** Subjective pain (*top*) and vision (*bottom*) on all postoperative days (Day 0 = day of surgery).

days required for complete reepithelialization or in the subjective evaluation of pain or vision between the 2 lenses at any time. Engle et al.<sup>10</sup> found significantly faster corneal reepithelialization and reduced patient discomfort during the first 48 hours after PRK in the eyes with a lotrafilcon A bandage contact lens than in eyes with a hydrogel bandage contact lens. Although there was no significant correlation between discomfort and defect size on any postoperative day with either bandage contact lens, our study found that larger epithelial defects at 3 days were associated with higher levels of pain with both lens types. It is not clear why Engle et al. did not find a significant correlation because larger epithelial defects should cause greater discomfort as a result of greater sensory nerve exposure. Moreover, in our study, patients reported increased discomfort postoperatively, although complete reepithelialization may have already occurred. This might be because the oral medication for pain control, which would likely result in underestimation of subjective evaluation of pain, had been discontinued by that time. However, in addition to the major role of corneal sensory nerves, other factors might play a part in pain sensation.

Furthermore, in the subjective vision evaluation, all patients reported that vision on the third postoperative day was worse than on the earlier 2 postoperative days. This was not unexpected because the epithelial healing process takes place at the center of the cornea at that time.


Although the 2 types of bandage contact lenses used in our study differ in the back optic zone radius and diameter, there were no significant differences between the 2 lenses fitted in post-blink lens movement and centration, corneal coverage, or tear-film thickness after the lens was removed (all assessed using specular reflection). The basic fitting philosophy, as previously suggested,<sup>20</sup> was to provide adherence and stabilization, allowing for less than normal mobility. On the other hand, some tear exchange should be conserved to provide sufficient oxygen to the corneal periphery for metabolic changes to occur in the regenerating corneal epithelium. Seo et al.<sup>21</sup> showed that a flat-fitted bandage contact lens after LASEK results in shorter epithelial healing time than a steep-fitted lens. However, it is important to differentiate between the role of a bandage contact lens fitted after LASEK and the role after PRK. After LASEK, the key action of the bandage contact lens is to accelerate the wound-healing response of the corneal epithelium. After PRK, the bandage contact lens should promote stabilization and complete corneal reepithelialization. Based on this, we fit bandage contact lenses tighter than normal to prevent excessive lens movement that could cause further trauma to the central cornea or patient discomfort.

In conclusion, as have previous studies, our study found that contact lenses of silicone elastomer materials can be used as an effective and well-tolerated bandage after refractive surgery.<sup>5,9,10</sup> Furthermore, we show for the first time that in addition to the lotrafilcon A contact lens with its established efficacy, the lotrafilcon B contact lens can be used as an effective bandage after PRK because of the limited time (4 to 5 days) usually required for complete corneal reepithelialization.

## REFERENCES

- Ghadhfan F, Al-Rajhi A, Wagoner MD. Laser in situ keratomileusis versus surface ablation: visual outcomes and complications. *J Cataract Refract Surg* 2007; 33:2041–2048
- El-Maghraby A, Salah T, Waring GO III, Klyce S, Ibrahim O. Randomized bilateral comparison of excimer laser in situ keratomileusis and photorefractive keratectomy for 2.50 to 8.00 diopters of myopia. *Ophthalmology* 1999; 106:447–457
- Shahinian L Jr. Laser-assisted subepithelial keratectomy for low to high myopia and astigmatism. *J Cataract Refract Surg* 2002; 28:1334–1342
- Anderson NJ, Beran RF, Schneider TL. Epi-LASEK for the correction of myopia and myopic astigmatism. *J Cataract Refract Surg* 2002; 28:1343–1347
- Gil-Cazorla R, Teus MA, Hernández-Verdejo JL, de Benito-Llopis L, García-González M. Comparative study of two silicone hydrogel contact lenses used as bandage contact lenses after LASEK. *Optom Vis Sci* 2008; 85:884–888
- Cherry PMH. The treatment of pain following excimer laser photorefractive keratectomy: additive effect of local anesthetic drops, topical diclofenac, and bandage soft contact. *Ophthalmic Surg Lasers* 1996; 27:S477–S480
- McDonald MB, Deitz MR, Frantz JM, Kraff MC, Krueger RR, Salz JJ, Kraff CR, Maguen E, Matta CS, Nesburn AB, Piebenga LW. Photorefractive keratectomy for low-to-moderate myopia and astigmatism with a small-beam, tracker-directed excimer laser. *Ophthalmology* 1999; 106:1481–1488; discussion by RD Stulting, 1488–1489
- Demers P, Thompson P, Bernier RG, Lemire J, Laflamme P. Effect of occlusive pressure patching on the rate of epithelial wound healing after photorefractive keratectomy. *J Cataract Refract Surg* 1996; 22:59–62
- Szaflik JP, Ambroziak AM, Szaflik J. Therapeutic use of a lotrafilcon A silicone hydrogel soft contact lens as a bandage after LASEK surgery. *Eye Contact Lens* 2004; 30:59–62
- Engle AT, Laurent JM, Schallhorn SC, Toman SD, Newacheck JS, Tanzer DJ, Tidwell JL. Masked comparison of silicone hydrogel lotrafilcon A and etafilcon A extended-wear bandage contact lenses after photorefractive keratectomy. *J Cataract Refract Surg* 2005; 31:681–686
- Foulks GN. Prolonging contact lens wear and making contact lens wear safer. *Am J Ophthalmol* 2006; 141:369–373
- Nilsson SEG. Seven-day extended wear and 30-day continuous wear of high oxygen transmissibility soft silicone hydrogel contact lenses: a randomized 1-year study of 504 patients. *CLAO J* 2001; 27:125–136
- Sedláček J. [Possibilities of application of eye drugs with the aid of gel-contact lenses]. [Czechoslovakian] *Cesk Oftalmol* 1965; 21:509–512
- Gasset AR, Kaufman HE. Therapeutic uses of hydrophilic contact lenses. *Am J Ophthalmol* 1970; 69:252–259

15. Gould HL. Therapeutic contact lenses. *Int Ophthalmol Clin* 1970; 10(1):131–141
16. Bergenske PD, Caroline PJ, Smythe JK. Contact lens as an adjunct in refractive surgery practice. *Contact Lens Spectrum* 2002; 17(3):30–37. Available at <http://www.clspectrum.com/article.aspx?article=12116>. Accessed September 14, 2009
17. Cavanagh HD, Ladage PM, Li SL, Yamamoto K, Molai M, Ren DH, Petroll WM, Jester JV. Effects of daily and overnight wear of a novel hyper oxygen-transmissible soft contact lens on bacterial binding and corneal epithelium; a 13-month clinical trial. *Ophthalmology* 2002; 109:1957–1969
18. Ren DH, Yamamoto K, Ladage PM, Molai M, Li L, Petroll WM, Jester JV, Cavanagh HD. Adaptive effects of 30-night wear of hyper-O<sub>2</sub> transmissible contact lenses on bacterial binding and corneal epithelium; a 1-year clinical trial. *Ophthalmology* 2002; 109:27–39; invited comment by PC Donshik, 39–40
19. Montero J, Sparholt J, Mély R, Long B. Retrospective case series of therapeutic applications of lotrafilcon A silicone hydrogel soft contact lenses. *Eye Contact Lens* 2003; 29:72–75
20. de Oliveira PR, Bailey MD. Therapeutic contact lenses. In: Mannis MJ, Zadnik K, Coral-Ghanem C, Kara-José N, eds, *Contact Lenses in Ophthalmic Practice*. New York, NY, Springer, 2004; 197–203
21. Seo JH, Wee WR, Lee JH, Kim MK. Effect of base curve radius of therapeutic lenses on epithelial healing after laser-assisted subepithelial keratectomy. *Korean J Ophthalmol* 2007; 21:85–89. Available at <http://synapse.koreamed.org/Synapse/Data/PDFData/0065KJO/kjo-21-85.pdf>. Accessed September 14, 2009



First author:

Michael A Grentzelos, MD

*Institute of Vision and Optics,  
Faculty of Medicine, University of  
Crete, Heraklion, Crete, Greece*