

# Endothelial cell density after photorefractive keratectomy for moderate myopia using a 213 nm solid-state laser system

Nikolaos S. Tsiklis, MD, MSc, George D. Kymionis, MD, PhD, Aristofanis I. Pallikaris, MSc, Vasilios F. Diakonis, MD, Harilaos S. Ginis, PhD, George A. Kounis, Sophia I. Panagopoulou, PhD, Ioannis G. Pallikaris, MD, PhD

**PURPOSE:** To evaluate whether photorefractive keratectomy (PRK) for moderate myopia using a solid-state laser with a wavelength of 213 nm alters the corneal endothelial cell density.

**SETTING:** University refractive surgery center.

**METHODS:** The corneal endothelium was analyzed preoperatively and 1, 6, and 12 months postoperatively using corneal confocal microscopy (modified HRT II with a Rostock Cornea Module, Heidelberg Engineering) in 60 eyes (30 patients). Patients were randomized to have myopic PRK using a 213 nm wavelength solid-state laser (study group) or a conventional 193 nm wavelength excimer laser (control group). Three endothelial images were acquired in each of 30 preoperative normal eyes to evaluate the repeatability of endothelial cell density measurements. Repeated-measures analysis of variance was used to compare the variations in endothelial cell density between the 2 lasers and the changes in endothelial cell density over time.

**RESULTS:** There were no statistically significant differences in sex, age, corneal pachymetry, attempted correction, preoperative endothelial cell density, or postoperative refractive outcomes (uncorrected visual acuity, best spectacle-corrected visual acuity, and spherical equivalent refraction) between the 2 groups ( $P > .05$ ). The coefficient of repeatability of endothelial cell density was 131 cells/mm<sup>2</sup>. The measured endothelial cell count per 1.0 mm<sup>2</sup> did not significantly change up to 1 year postoperatively in either group (both  $P > .05$ ). No statistically significant difference was found between the 2 groups in any postoperative interval ( $P > .05$ ).

**CONCLUSION:** Photorefractive keratectomy for moderate myopia using a 213 nm wavelength solid-state laser or a conventional 193 nm wavelength excimer laser did not significantly affect corneal endothelial density during the 1-year postoperative period.

*J Cataract Refract Surg 2007; 33:1866–1870 © 2007 ASCRS and ESCRS*

For more than 20 years, corneal photoablation using an excimer laser has proved to be a safe and effective procedure.<sup>1–3</sup> Despite the preliminary results in experimental studies<sup>4–7</sup> showing endothelial cell changes when high corrections were attempted, in vivo clinical trials<sup>8–21</sup> found no adverse effects to the corneal endothelium after refractive surgery using an excimer laser.

Recently, as an alternative to traditional excimer laser systems (193 nm wavelength), many surgeons began using solid-state lasers with promising results.<sup>22–26</sup> These laser platforms have a 213 nm wavelength, which provides several theoretical and practical advantages over the excimer laser. The 213 nm

wavelength is closer to the absorption peak of corneal collagen and is less sensitive to corneal hydration. Solid-state lasers have higher pulse-to-pulse energy stability, a smaller spot size (0.6 mm), and lower maintenance costs because they do not require expensive gases. Furthermore, they are safer because the gases used with conventional systems are toxic and require special handling.

The purpose of this study was to investigate the possible effect of a solid-state laser with a 213 nm wavelength on the corneal endothelium after myopic photorefractive keratectomy (PRK) and to compare the results with those of PRK using an excimer laser.

## PATIENTS AND METHODS

This prospective comparative analysis comprised 30 patients (60 eyes) with bilateral myopia. The study was approved by the institutional review board. Before their participation, all patients were informed about the nature of the study and gave informed consent in accordance with institutional guidelines and the Declaration of Helsinki.

Exclusion criteria were active anterior segment disease, previous intraocular or corneal surgery, history of herpes keratitis, diagnosed autoimmune disease, systemic connective tissue disease or atopic syndrome, and corneal topographic findings suspicious for keratoconus.

The study group included 15 patients (30 eyes) who had PRK using a 213 nm wavelength solid-state laser (Pulzar Z1 Laser System, CustomVis). The control group consisted of 15 patients (30 eyes) who had PRK with a conventional 193 nm wavelength excimer laser system (Allegretto 400 Hz, WaveLight Technologie AG). The patients were randomly assigned to the study group or control group.

### Surgical Technique

At surgery, the corneal epithelium was removed mechanically using a rotating brush in all cases. After the laser ablation, a soft contact lens was placed on the cornea. Both groups had PRK by the same surgeon (I.G.P.) using an identical technique and nomogram.

### Clinical Examinations

Before PRK, all patients had a full ophthalmologic examination including manifest and cycloplegic refractions, uncorrected visual acuity (UCVA), best spectacle-corrected visual acuity (BSCVA), slitlamp biomicroscopy, Goldmann applanation tonometry, fundus evaluation, ultrasound pachymetry and corneal topography, and confocal microscopy. After PRK, all patients were monitored daily until complete epithelial healing, at which time the therapeutic contact lenses were removed.

Preoperative and postoperative follow-up (at 1, 6, and 12 months) included endothelial cell density assessment by the same examiner (V.F.D.), who was unaware of the laser used in the surgical procedures. Corneal confocal microscopy was performed with a modified confocal scanning laser ophthalmoscope (HRT II, Heidelberg Engineering) using the manufacturer's software. The principle of operation of the modified scanning laser ophthalmoscope has been described.<sup>27</sup>

Accepted for publication June 11, 2007.

From the Department of Ophthalmology (Tsiklis, Kymionis, I.G. Pallikaris) and Institute of Vision and Optics (Tsiklis, Kymionis, A.I. Pallikaris, Diakonis, Ginis, Kounis, Panagopoulou, I.G. Pallikaris), University of Crete, Crete, Greece.

No author has a financial or proprietary interest in any material or method mentioned.

Corresponding author: Nikolaos S. Tsiklis, MD, MSc, Institute of Vision and Optics, University of Crete, Medical School, Department of Ophthalmology, 71003 Heraklion, Crete, Greece. E-mail: ntsiklis@hotmail.com.

## Statistical Analysis

To assess the repeatability of the instrument, 3 images of the endothelium were acquired in each of the 30 normal subjects and were used by an experienced operator to count the endothelial cell density. Measurement error and statistical analysis were performed using techniques described by Bland and Altman.<sup>28</sup> The standard deviation of measurement was regressed against the mean of the 3 counts to examine the relationship between standard deviation and magnitude of measurement, while the repeatability of the instrument was expressed as 2 times the within-subject standard deviation as described by Bland and Altman.

An analysis of variance with repeated measures (over time) was performed to assess the effect of the 2 lasers on the temporal changes in endothelial cell density (preoperatively and 1, 6, and 12 months postoperatively).

## RESULTS

Table 1 shows the patients' demographics, preoperative refractive data, and attempted ablation depth. There were no intraoperative or early or late postoperative complications in any eye.

### Visual Acuity and Refraction

At the 1-year postoperative examination, all eyes in both groups had a UCVA of 20/25 or better; 27 eyes (90.0%) in the excimer laser group and 28 eyes (93.3%) in the solid-state group had a UCVA of 20/20 or better. No eye in either group lost a line of Snellen BSCVA; 3 eyes (10.0%) in the excimer laser group and 4 eyes (13.3%) in the solid-state laser group gained 1 line of Snellen BSCVA.

The spherical equivalent (SE) refraction was within  $\pm 0.75$  diopter (D) of emmetropia in all eyes in both groups. There was a mean reduction from  $-3.34 \pm 0.59$  (SD) (range  $-2.00$  to  $-4.63$  D) to  $-0.33 \pm 0.55$  D (range  $0.25$  to  $-0.75$  D) in the solid-state laser group and from  $-3.41 \pm 0.51$  D (range  $-1.75$  to  $-4.50$  D) to  $-0.36 \pm 0.56$  D (range  $0.38$  to  $-0.63$  D) in the excimer laser group.

At 1 year, there were no statistically significant differences in refractive outcomes (UCVA, BSCVA, SE refraction) between the 2 laser groups ( $P > .05$ ).

### Endothelial Cell Density

The standard deviation of the endothelial cell measurement was not related to the magnitude of measurement as indicated by the Kendall  $\tau$  rank correlation coefficient (0.02;  $P = .90$ ) and regression analysis (slope not significantly different from zero;  $P = .68$ ). Moreover, the repeatability of measurement, expressed as 2 times the within-subject standard deviation, was 131 cells/mm<sup>2</sup> (Figure 1).

Table 2 shows the confocal microscopy endothelial cell density measurements at each examination in

**Table 1.** Patient demographics and refractive data.

Parameter	Solid State Laser (Study Group)	Excimer Laser (Control Group)	P Value
No of eyes/patients	30/15	30/15	—
Sex (male/female)	8/7	7/8	.77
Age (y)			
Mean $\pm$ SD	28.80 $\pm$ 7.07	29.10 $\pm$ 6.98	.84
Range	18 to 42	20 to 45	
Preop corneal pachymetry ( $\mu$ m)			
Mean $\pm$ SD	540.90 $\pm$ 22.30	544.70 $\pm$ 23.80	.65
Range	498 to 570	489 to 576	
Preop spherical equivalent (D)			
Mean $\pm$ SD	-3.34 $\pm$ 0.59	-3.41 $\pm$ 0.56	.74
Range	-2.00 to -4.63	-1.75 to -4.50	
Preop cylinder (D)			
Mean $\pm$ SD	-0.48 $\pm$ 0.26	-0.46 $\pm$ 0.23	.69
Range	0.00 to -0.75	0.00 to -0.75	
Attempted ablation depth ( $\mu$ m)			
Mean $\pm$ SD	54.60 $\pm$ 9.71	53.40 $\pm$ 9.54	.76
Range	31 to 72	27 to 70	

both groups. There was no significant difference in the preoperative endothelial cell count between the 2 groups ( $P > .05$ ). A repeated-measures analysis of cell density variance did not indicate statistically significant differences in mean endothelial cell density at any postoperative interval measurement in either group ( $P > .05$ ).

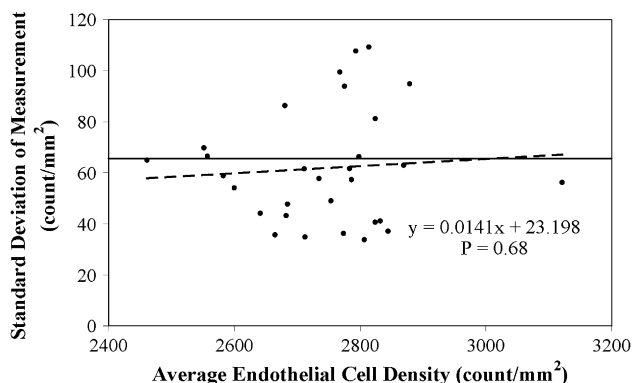
## DISCUSSION

Three main side effects of laser corneal ablation have been identified: thermal damage, mechanical stress due to the pressure wave, and actinic damage due to the primary (laser beam) and secondary (fluorescence) radiation.<sup>1</sup> The extent of primary actinic damage depends primarily on the absorption coefficient of the cornea,<sup>29</sup> and secondary actinic damage depends on

the spectrum and the intensity of the fluorescence. The cornea exhibits a very high absorption coefficient at both laser wavelengths<sup>25,30,31</sup>; therefore, primary actinic damage is expected to be restricted to small depths in both cases. However, the potential implication of corneal stroma and endothelium to secondary (fluorescence) radiation cannot be estimated as little is known about the spectral characteristics of the fluorescence during 213 nm ablation of the cornea. Regarding the acoustic wave, the smaller beam size (0.60 mm diameter) of the 213 nm laser platform (approximately one third that of a typical excimer laser system; for example, 0.95 mm spot diameter with the Allegretto 400 Hz) produces less acoustic effect during the ablation,<sup>9</sup> a phenomenon that might correlate with endothelial cell changes.<sup>32</sup>

Refractive surgery<sup>8-21</sup> with the excimer laser has no significant adverse effect on the corneal endothelium. Mardeli et al.<sup>8</sup> found no alterations in corneal endothelial density even 55 months after PRK in myopic patients, and Collins et al.<sup>10</sup> found no detrimental effect on the corneal endothelium after laser in situ keratomileusis (LASIK) with the excimer laser. However, few studies in the literature report endothelial cell alterations after refractive surgery.<sup>7,29,33-36</sup> Most of them refer to patients with high attempted corrections or with a residual stromal bed that is too thin. Kim et al.<sup>36</sup> found there must be at least 200  $\mu$ m of intact corneal stroma postoperatively to protect the endothelial monolayer.

In the current study, the measured endothelial cell count per 1.0  $\text{mm}^2$  did not significantly change up to 1 year postoperatively in the solid-state laser group or the excimer laser group. No statistically significant



**Figure 1.** Relationship between standard deviation of measurement and magnitude of measurement. The dotted line represents the regression line and the solid line, the within-subject standard deviation.

**Table 2.** Endothelial cell density in eyes having PRK with a solid-state or excimer laser.

Group	Endothelial Cell Count (cells/mm <sup>2</sup> )			
	Preoperative*	1 Month*	6 Months*	12 Months <sup>†</sup>
Solid-state laser (study group)				
Mean ± SD	2633 ± 137	2629 ± 129	2617 ± 140	2648 ± 138
Range	2505 to 2875	2490 to 2870	2510 to 2895	2525 to 2900
P value	—	.96	.79	.92
Excimer laser (control group)				
Mean ± SD	2647 ± 133	2668 ± 145	2639 ± 135	2651 ± 142
Range	2495 to 2910	2480 to 2925	2485 to 2905	2470 to 2930
P value	—	.71	.90	.83

\*n = 30, both groups  
<sup>†</sup>n = 26, solid-state laser group; n = 28, excimer laser group

difference was found between the 2 groups at any postoperative interval ( $P > .05$ ). These results are in accordance with those in previous studies of PRK with the excimer laser, which showed no adverse effects on the corneal endothelium.<sup>8-17</sup> Moreover, the refractive outcomes (UCVA, BSCVA, SE refraction) were not statistically significantly different between the 2 laser groups up to 1 year postoperatively ( $P > .05$ ).

This study had several potential limitations. The major ones are the limited follow-up, lack of increased depth of ablation, and absence of endothelial cell morphology study (coefficient of variation of cell area and percentage of hexagonal cells).

In conclusion, our prospective comparative study found no statistically significant changes in corneal endothelial cell density up to 1 year after PRK performed with a solid-state (213 nm) or excimer (193 nm) laser for low to moderate myopic corrections. The small physical differences between the 2 laser platforms (Pulzar Z1 and Allegretto 400 Hz) seem to have no practical (clinical) importance in terms of endothelial cell loss. Future studies including more patients, different surgical techniques (LASIK, epi-LASIK), and higher attempted corrections are needed to draw final conclusions.

**REFERENCES**

1. Trokel SL, Srinivasan R, Braren B. Excimer laser surgery of the cornea. *Am J Ophthalmol* 1983; 96:710-715
2. Kymionis GD, Tsiklis NS, Astyrakakis N, et al. Eleven-year follow-up of laser in situ keratomileusis. *J Cataract Refract Surg* 2007; 33:191-196
3. O'Connor J, O'Keefe M, Condon PI. Twelve-year follow-up of photorefractive keratectomy for low to moderate myopia. *J Refract Surg* 2006; 22:871-877
4. Marshall J, Trokel S, Rothery S, Schubert H. An ultrastructural study of corneal incisions induced by excimer laser at 193 nm. *Ophthalmology* 1985; 92:749-758
5. Gaster RN, Binder PS, Cooyalwell K, et al. Corneal surface ablation by 193 nm excimer laser and wound healing in rabbits. *Invest Ophthalmol Vis Sci* 1989; 30:90-98
6. Hanna KD, Pouliquen Y, Waring GO III, et al. Corneal stromal wound healing in rabbits after 193-nm excimer laser surface ablation. *Arch Ophthalmol* 1989; 107:895-901
7. Berns MW, Liaw L-H, Oliva A, et al. An acute light and electron microscopic study of ultraviolet 193-nm excimer laser corneal incisions. *Ophthalmology* 1988; 95:1422-1433
8. Mardelli PG, Piebenga LW, Matta CS, et al. Corneal endothelial status 12 to 55 months after excimer laser photorefractive keratectomy. *Ophthalmology* 1995; 102:544-548; discussion by PS Binder, 548-549
9. McDonald MB, Deitz MR, Frantz JM, et al. Photorefractive keratectomy for low-to-moderate myopia and astigmatism with a small-beam, tracker-directed excimer laser. *Ophthalmology* 1999; 106:1481-1488; discussion by RD Stulting, 1488-1489
10. Collins MJ, Carr JD, Stulting RD, et al. Effects of laser in situ keratomileusis (LASIK) on the corneal endothelium 3 years postoperatively. *Am J Ophthalmol* 2001; 131:1-6
11. Amano S, Shimizu K. Corneal endothelial changes after excimer laser photorefractive keratectomy. *Am J Ophthalmol* 1993; 116:692-694
12. Carones F, Brancato R, Venturi E, Morico A. The corneal endothelium after myopic excimer laser photorefractive keratectomy. *Arch Ophthalmol* 1994; 112:920-924
13. Isager P, Hjortdal JØ, Ehlers N. The effect of 193 nm excimer laser radiation on the human corneal endothelial cell density. *Acta Ophthalmol Scand* 1996; 74:224-227
14. Spadea L, Dragani T, Blasi MA, et al. Specular microscopy of the corneal endothelium after excimer laser photorefractive keratectomy. *J Cataract Refract Surg* 1996; 22:188-193
15. Cennamo G, Rosa N, Del Prete A, et al. The corneal endothelium 12 months after photorefractive keratectomy in high myopia. *Acta Ophthalmol Scand* 1997; 75:128-130
16. Kent DG, Solomon KD, Peng Q, et al. Effect of surface photorefractive keratectomy and laser in situ keratomileusis on the corneal endothelium. *J Cataract Refract Surg* 1997; 23:386-397
17. Jabbur NS. Endothelial cell studies in patients after photorefractive keratectomy for hyperopia; the VISX STAR Excimer Laser System Hyperopia Study Group. *J Refract Surg* 2003; 19:142-148
18. Pérez-Santonja JJ, Sakla HF, Gobbi F, Alió JL. Corneal endothelial changes after laser in situ keratomileusis. *J Cataract Refract Surg* 1997; 23:177-183
19. Pérez-Santonja JJ, Sakla HF, Alió JL. Evaluation of endothelial cell changes 1 year after excimer laser in situ keratomileusis. *Arch Ophthalmol* 1997; 115:841-846

20. Jones SS, Azar RG, Cristol SM, et al. Effects of laser in situ keratomileusis (LASIK) on the corneal endothelium. *Am J Ophthalmol* 1998; 125:465–471
21. Nawa Y, Ueda T, Masuda K, et al. Evaluation of the corneal endothelium after hyperopic laser in situ keratomileusis. *J Cataract Refract Surg* 2003; 29:1543–1545
22. Anderson I, Sanders DR, van Saarloos P, Ardrey WJ IV. Treatment of irregular astigmatism with a 213 nm solid-state, diode-pumped neodymium:YAG ablative laser. *J Cataract Refract Surg* 2004; 30:2145–2151
23. Roszkowska AM, Korn G, Lenzner M, et al. Experimental and clinical investigation of efficiency and ablation profiles of new solid-state deep-ultraviolet laser for vision correction. *J Cataract Refract Surg* 2004; 30:2536–2542
24. Roszkowska AM, De Grazia L, Ferreri P, Ferreri G. One-year clinical results of photorefractive keratectomy with a solid-state laser for refractive surgery. *J Refract Surg* 2006; 22:611–613
25. Dair GT, Pelouch WS, van Saarloos PP, et al. Investigation of corneal ablation efficiency using ultraviolet 213-nm solid state laser pulses. *Invest Ophthalmol Vis Sci* 1999; 40:2752–2756
26. Tsiklis NS, Kymionis GD, Kounis GA, et al. One-year results of photorefractive keratectomy and laser in situ keratomileusis for myopia using a 213 nm wavelength solid-state laser. *J Cataract Refract Surg* 2007; 33:971–977
27. Kymionis GD, Tsiklis NS, Pallikaris AI, et al. Long-term follow-up of Intacs for post-LASIK corneal ectasia. *Ophthalmology* 2006; 113:1909–1917
28. Bland JM, Altman DG. Statistical methods for assessing agreement between two methods of clinical measurements. *Lancet* 1986; 1:307–310
29. Lembares A, Hu X-H, Kalmus GW. Absorption spectra of corneas in the far ultraviolet region. *Invest Ophthalmol Vis Sci* 1997; 38:1283–1287
30. Hu X-H, Juhasz T. Study of corneal ablation with picosecond laser pulses at 211 nm and 263 nm. *Lasers Surg Med* 1996; 18:373–380
31. Kermani O, Koort HJ, Roth E, Dardenne MU. Mass spectroscopic analysis of excimer laser ablated material from human corneal tissue. *J Cataract Refract Surg* 1988; 14:638–641
32. Krueger RR, Seiler T, Gruchman T, et al. Stress wave amplitudes during laser surgery of the cornea. *Ophthalmology* 2001; 108:1070–1074
33. Trocmé SD, Mack KA, Gill KS, et al. Central and peripheral endothelial cell changes after excimer laser photorefractive keratectomy for myopia. *Arch Ophthalmol* 1996; 114:925–928
34. Isager P, Guo S, Hjortdal JØ, Ehlers N. Endothelial cell loss after photorefractive keratectomy for myopia. *Acta Ophthalmol Scand* 1998; 76:304–307
35. Pallikaris IG, Siganos DS. Excimer laser in situ keratomileusis and photorefractive keratectomy for correction of high myopia. *J Refract Corneal Surg* 1994; 10:498–510
36. Kim K-S, Jeon S-J, Edelhauser HF. Corneal endothelial morphology and barrier function following excimer laser photorefractive keratectomy. In: Lass JH, ed, *Advances in Corneal Research; Selected Transactions of the World Congress on the Cornea IV*. New York, NY, Plenum Press, 1997; 329–342



First author:

Nikolaos S. Tsiklis, MD, MSc

*Department of Ophthalmology  
and Institute of Vision and Optics,  
University of Crete, Crete, Greece*