

Induced Videokeratography Alterations in Patients With Excessive Meibomian Secretions

Marinos M. Markomanolakis, MD,*‡ George D. Kymionis, MD, PhD,*†
Ioannis M. Aslanides, MD, PhD,* Nikolaos Astyrakakis, OD,* and Ioannis G. Pallikaris, MD, PhD*†

Purpose: To describe lipid-induced specific videokeratographic (VKG) corneal changes and subsequent resolution after eyelid washing.

Methods: VKG was performed with C-Scan corneal topography. In all patients an excessive meibomian gland lipid secretion was found with or without coexistent chronic posterior blepharitis. After the initial VKG, a meticulous cleaning of the lids with a mild alkali shampoo (10% Johnson's baby shampoo in sterile water) was done, first by gently scrubbing the closed eyelid fissure with the solution to mobilize and emulsify any Meibomian gland secretions followed by cleaning of the upper and lower margins individually, using Q-tip applicators soaked in the detergent.

Results: Three patients with tear film lipid layer excess (TFLE), which correlated with the presence of a superior or central corneal steepening in VKG, were studied. In two of the subjects, careful lid washing reversed either completely or partially this VKG effect, whereas in the last patient the VKG changes after artificially increasing the tear film lipid content is described.

Conclusions: Meibomian gland lipid secretions may induce mainly superior and occasionally central VKG corneal steepening that is not correlated with any slit-lamp pathologic findings. Computerized corneal topography can help detect such corneal abnormalities, and their reversibility may distinguish them from other pathologic conditions (such as contact lens-induced warpage, eccentric ablations, irregular astigmatism, superior keratoconus).

Key Words: corneal topography, meibomian secretions, eyelid washing

(*Cornea* 2005;24:16–19)

The meibomian glands, located within the tarsal plates, are responsible for the secretion of the lipid layer in the tear film. The principal function of the lipid layer is to limit evaporative tear loss, provide a barrier function at the lid margin, supply lubrication during blinking, and maintain an optically smooth surface. In parallel, the presence of a smooth lipid layer is essential as a refractive element because it constitutes the first air–liquid interface in the ocular focusing apparatus.

Analyses of the meibomian gland lipids from normal subjects suggest that there are large variations among individuals.¹ Excessive secretions have been described as an entity with a recognizable seborrhea of the meibomian glands.² Lipid layer thickness has been reported to vary from 13 to 170 nm.^{3,4} That thickness is dependent on several major factors including meibomian gland function, composition of gland secretions, effectiveness of blinking, width of the interpalpebral fissure, and ambient humidity.

The purpose of this study is to report a superior or central reversible corneal topographic steepening in VKG in patients with increased meibomian gland secretions and the subsequent resolution after eyelid washing.

MATERIALS AND METHODS

The study population consisted of 3 patients visiting a University Refractive Surgery Unit (Vardinoyannion Eye Institute of Crete, University of Crete, Heraklion, Crete, Greece).

All patients were appropriately informed before their participation in the study and gave their written informed consent in accordance with institutional guidelines, according to the Declaration of Helsinki.

In all patients an excessive meibomian gland lipid secretion was found with or without coexistent chronic posterior blepharitis. A complete ophthalmologic examination was performed to exclude other ocular disease. Uncorrected visual acuity (UCVA) and best corrected visual acuity (BCVA), manifest refraction, and corneal topography (C-Scan/Technomed GmbH, Germany) were also examined.

All corneal topographies were performed with the patient instructed to blink several times before the procedure without performing any pressure on the cornea. After the initial VKG, a meticulous cleaning of the lids with a mild alkali

Received for publication August 4, 2003; revision received December 12, 2003; accepted January 13, 2004.

From the *Vardinoyannion Eye Institute of Crete, Crete, Greece; †Department of Ophthalmology, University of Crete, Crete, Greece; and ‡Ophthalmology Associates PC, Birmingham, Alabama.

Reprints: George D. Kymionis, MD, PhD, University of Crete, VEIC, Medical School Department of Ophthalmology, 71110 Heraklion, Crete, Greece (e-mail: kymionis@med.uoc.gr).

Copyright © 2004 by Lippincott Williams & Wilkins

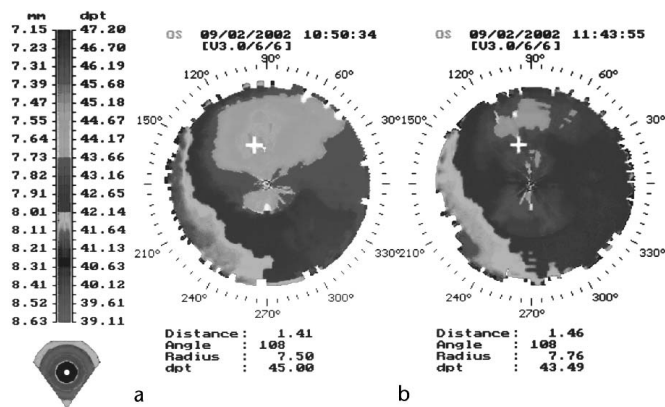
shampoo (10% Johnson's baby shampoo in sterile water) was done, first by gently scrubbing the closed eyelid fissure with the solution to mobilize and emulsify any meibomian gland secretions followed by cleaning of the upper and lower margins individually, using Q-tip applicators soaked in the detergent. The patient was then allowed to blink several times; all the residual detergent was irrigated from the eyelids and the conjunctival sacs using gauze soaked in sterile water. After the washing procedure, the corneal topography was repeated.

Two observers in a masked fashion analyzed corneal topography, and interobserver reliability was tested.

Case 1

A 47-year-old man was referred for treatment of hyperopia. His past medical and ocular history were negative. Examination showed UCVA 20/40 and 20/50 in his right (OD) and left (OS) eyes, respectively. BCVA was 20/20 in both eyes (OU), and manifest refraction (MR) was +3.50/-0.75 × 165° and +2.50 D in the right and the left eyes, respectively. Slit-lamp examination was without pathologic findings except for a moderate degree of posterior blepharitis bilaterally with facial features of rosacea and tear film lipid layer excess (TFLE) OU.

Computerized corneal topography (C-Scan/Technomed GmbH, Germany) was obtained and revealed a superior corneal asymmetry in both eyes. This topographic steepening was rather isolated from the central astigmatism, appearing as a "cloud" on the superior cornea. Because the topographic asymmetry was more significant in the left eye (Fig. 1a), we proceeded with eyelid washing with the mild alkali shampoo solution using the procedure described above. After washing, slit-lamp reexamination showed the absence of lipid in the tear film, and the VKG was retaken, demonstrating a substantial improvement in the topographic findings (Fig. 1b).



TECHNOMED

FIGURE 1. Preoperative corneal topography demonstrating the alterations in superior topographic "cloud-like" asymmetry before (a, right) and after (b, left) eyelid washing.

Case 2

A 46-year-old woman was referred for myopia correction. Her ophthalmologic history was negative except for soft contact lens wear and occasional foreign body sensation in both eyes. Uncorrected visual acuity was count fingers in both eyes correctable to 20/20 with the following manifest refraction: OD -4.75/-1.25 × 90° and OS -4.50/-0.50 × 80°. Slit-lamp examination revealed moderate posterior blepharitis of both eyes with excessive meibomian secretions. Both corneas and lenses were clear.

An increased tear film lipid layer and posterior blepharitis were the only findings in the patient's last examination, and she had been (soft) contact lens-free for the past 3 months.

To evaluate the possible effect of the increased lipid layer in the tear film, we massaged the upper eyelids with the patient looking down in both eyes, expressing more meibomian secretions in the tear film, and then repeated the topography, which demonstrates that the tear film lipid composition indeed had a predictable effect on the superior steepening configuration (OD), whereas in the left eye the topographic pattern changed more toward increasing the central steepening (Fig. 2).

Case 3

A 42-year-old man was referred for correction of his myopia. His past ocular history was significant for a mild bilateral optic nerve hypoplasia and soft contact lens use in both eyes, discontinued 3 weeks before his preoperative examination. UCVA was counting fingers in both eyes, and BCVA was 20/40 and 20/25 with -7.75 - 1.75 × 80° and -5.75 - 0.50 × 145° in the right and left eyes, respectively.

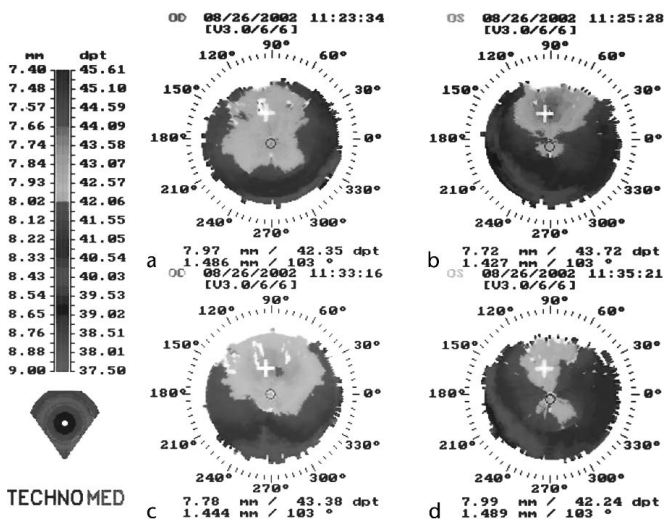


FIGURE 2. Before (a, b, top) and after (c, d, bottom) upper eyelid massage topographies, showing the superior steepening configuration in the right eye while, in the left eye, the topographic pattern changed more toward increasing the central steepening.

The patient underwent uncomplicated bilateral LASIK. Two days postoperatively, topography revealed a relatively symmetric central bilateral ablation pattern in both eyes (Fig. 3a,b). Six weeks postoperatively, there was a tendency for superior corneal steepening more in the left eye reminiscent of eccentric ablation or early post-LASIK corneal ectasia (Fig. 3c,d).

Seven months postoperatively, the clinical picture (UCVA, BSCVA, and manifest refraction) was essentially unchanged (OD $-0.50/-0.75 \times 30^\circ$, OS -0.75 D) from the 6-week follow-up visit. During slit-lamp examination in his last follow-up, a significant degree of posterior blepharitis was noticed with lipid layer overproduction and rosacea-like facial features. Cleaning of the eyelids in the left eye essentially reversed the superior corneal steepening and substantially improved the “eccentric inferior ablation” pattern in the previous topography (Fig. 4).

DISCUSSION

Assessment of the corneal topography has become an indispensable tool during preoperative screening of candidates for refractive surgery. It also constitutes the main objective test used to evaluate the corneal refractive operative outcome and occasionally as a guide for customized corneal laser ablations. The nature of any topographic asymmetries present in a corneal refractive surgery candidate must be meticulously explored to identify patients who can have poor surgical outcome because of a preexistent evolving pathologic process such as keratoconus, or whose corneal surface has been altered from contact lens use (warpage) and whose surgery needs to be post-

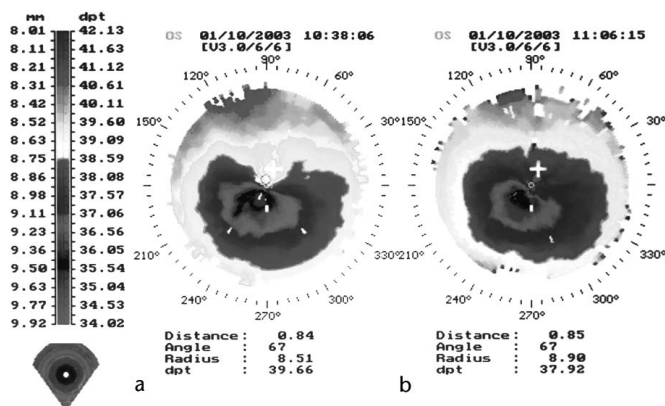


FIGURE 4. Topography before (right, a) and after (left, b) cleaning of the eyelids in the left eye essentially reversed the superior corneal steepening and substantially improved the “eccentric inferior ablation” pattern.

poned. Topographic asymmetries on a cornea after refractive surgery may also be an indication of an intraoperative complication (eccentric ablation) or even an early sign of a structurally unstable cornea as in iatrogenic ectasia, which may have poor prognosis for rehabilitation without visual aids (glasses or contact lenses) or even additional surgery.

There are several studies that correlate the status of the tear film with VKG findings.⁵ Liu and Pflugfelder⁶ demonstrated that patients with severe aqueous deficiency had irregular corneal surfaces and that instillation of artificial tears not only relieved these patients’ ocular irritation but also smoothed out the corneal surface irregularities and improved visual function. Huang et al⁷ suggested that tear film changes in dry eye patients may lead to irregularities on the corneal surfaces, causing glare disability, and significant improvement in corneal topography indexes was found in these patients after instillation of artificial tears. Furthermore, chronic ocular desiccation and aqueous tear deficiency can produce inferior corneal steepening and high astigmatism resembling keratoconus,⁸ and other studies have correlated chronic ocular rosacea with topographic finding such as inferior steepening in the videokeratoscopy.⁹

In our study all patients had an increased tear film lipid layer with or without chronic blepharitis observed in their slit-lamp examination. The best way to reveal the lipid layer in the tear film, during slit-lamp examination, is focusing at the most anterior corneal surface under high magnification while having a medium-width slit beam shone at a 60-degree angle from the observer’s line of sight on the cornea. Next, evaluation of the lid margin may show the presence of increased meibomian gland secretions and any signs of posterior blepharitis. A superior corneal topographic steepening that could be instantly reversed after washing the eyelids with a mild detergent solution (shampoo) was found. A possible explanation for this phe-

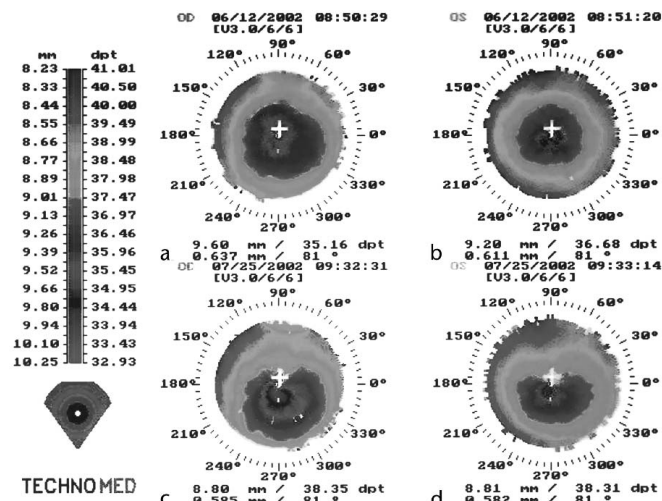


FIGURE 3. Two days post-LASIK, topographies (a, b, top) revealed a relatively symmetric central bilateral ablation pattern, whereas 6 weeks after LASIK treatment there was a tendency for superior corneal steepening (c, d, bottom) reminiscent of eccentric ablation or early post-LASIK corneal ectasia.

nomenon can be hypothesized to be the tendency of a lipid layer to “float” when mixed with an aqueous medium. Because the patient assumes the upright head position during VKG testing, the excessive lipid layer will tend to accumulate more in the upper cornea, thus producing the observed steepening. As demonstrated in case 2, the TFLE can also have a different but predictable effect on the topography: that of a relatively symmetric steepening over a wide central area around the visual axis. That topographic picture seems to be another expression of the same phenomenon, depending on the distribution of the lipid layer, which in the latter case is more symmetric because of mechanical (more recent blinking) or chemical characteristics of the tear film. It can also be simply the result of excessive lipid layer, which occupies both the central and the peripheral cornea alike.

Lid scrubs are one of the oldest treatments for chronic blepharitis; in most cases this treatment is beneficial. However, some treatment solutions may be more effective than others. It has been suggested that the alkalinity of some soaps may be beneficial by decreasing the chemical formation of NO in the skin.¹⁰ In parallel, meibum thickness and tear breakup time both improved greatly after tetracycline treatment in patients with ocular rosacea. Tetracycline has also been observed to decrease bacterial (*S. epidermidis*) lipase activity in vitro. Free fatty acids in meibum from acne rosacea patients were also decreased by oral minocycline treatment.¹¹

It is interesting to note that even though the majority of the patients having the above described corneal topographic asymmetry had a coexistent tear film lipid layer excess, the opposite is not necessarily true. Not every superior corneal topographic steepening represents a tear film abnormality. There are certainly cases in which other factors (preexisting corneal scars, contact lens-induced changes, etc) can create similar topographic irregularities. In these cases, washing of the eyelids does not have any effect on the topography, which can be of diagnostic significance.

The 3 cases reported are representative of a growing number of patients found to have similar corneal topographic changes that can be instantly improved after eyelid washing and are invariably coexistent with lipid layer overproduction. Instillation of 1 drop of artificial tears or eyelid washing without a detergent solution either worsens or does not change the topographic asymmetry, proving that it is not merely the effect of a coexistent dry eye condition that could have been reversed by the eyelid-washing procedure.

Finally, for patients having unrealistically high expectations or who are highly vigilant toward even small imperfections of their refractive surgery outcome, an asymmetric postoperative corneal topography might become the ultimate tool of “proving” to their ophthalmologist that the surgery did not go as well as it should and sometimes even compel him to take additional steps in correcting those imperfections.

Awareness of the possibility that subjects with a normal corneal examination might have significant topographic irregularities attributable to the presence of tear film abnormalities that can be easily reversed, as shown in our study, may give the refractive surgeon an advantage for the proper management of these patients. The clinical significance of carefully examining not only the corneal surface per se but also the condition of the tear film and the eyelids can not be overemphasized because poor quality tear film will negatively affect both the quality of vision and the amount of discomfort experienced by the patient even if refractive surgery was technically perfect. Further follow-up and additional cases must be reviewed to draw final conclusions about the possible correlation of these findings with other pathologic entities.

REFERENCES

1. Tiffany JM. Individual variations in human meibomian lipid composition. *Exp Eye Res.* 1978;27:289–300.
2. McCulley JP, Shine WE. Changing concepts in the diagnosis and management of blepharitis. *Cornea.* 2000;19:650–658.
3. Goto E, Tseng SC. Kinetic analysis of tear interference images in aqueous tear deficiency dry eye before and after punctal occlusion. *Invest Ophthalmol Vis Sci.* 2003;44:1897–1905.
4. Isreb MA, Greiner VJ, Korb DR, et al. Correlation of lipid layer thickness measurements with fluorescein tear film break-up time and Schirmer's test. *Eye.* 2003;17:79–83.
5. Novak KD, Kohnen T, Chang-Godinich A, et al. Changes in computerized videokeratography induced by artificial tears. *J Cataract Refract Surg.* 1997;23:1023–1028.
6. Liu Z, Pflugfelder SC. Corneal surface regularity and the effect of artificial tears in aqueous tear deficiency. *Ophthalmology.* 1999;106:939–943.
7. Huang F-C, Tseng S-H, Shih M-H, et al. Effect of artificial tears on corneal surface regularity, contrast sensitivity, and glare disability in dry eyes. *Ophthalmology.* 2002;109:1934–1940.
8. de Paiva CS, Harris LD, Pflugfelder SC. Keratoconus-like topographic changes in keratoconjunctivitis sicca. *Cornea.* 2003;22:22–24.
9. Dursun D, Piniella AM, Pflugfelder SC. Pseudokeratoconus caused by rosacea. *Cornea.* 2001;20:668–669.
10. Weller R, Pattullo S, Smith L, et al. Nitric oxide is generated on the skin surface by reduction of sweat nitrate. *J Invest Dermatol.* 1996;107:327–331.
11. Dougherty JM, McCulley JP, Silvany RE, et al. The role of tetracycline in chronic blepharitis: inhibition of lipase production in staphylococci. *Invest Ophthalmol Vis Sci.* 1991;32:2970–2975.