

case reports

Intacs for early pellucid marginal degeneration

George D. Kymionis, MD, PhD, Ioannis M. Aslanides, MD, PhD,
Charalambos S. Siganos, MD, PhD, Ioannis G. Pallikaris, MD, PhD

A 42-year-old man had Intacs (Addition Technology Inc.) implantation for early pellucid marginal degeneration (PMD). Two Intacs segments (0.45 mm thickness) were inserted uneventfully in the fashion typically used for low myopia correction (nasal-temporal). Eleven months after the procedure, the uncorrected visual acuity was 20/200, compared with counting fingers preoperatively, while the best spectacle-corrected visual acuity improved to 20/25 from 20/50. Corneal topographic pattern also improved. Although the results are encouraging, concern still exists regarding the long-term effect of this approach for the management of patients with PMD.

J Cataract Refract Surg 2004; 30:230–233 © 2004 ASCRS and ESCRS

Pellucid marginal degeneration (PMD) is a bilateral, noninflammatory disorder characterized by a peripheral band of thinning of the inferior cornea.¹ Its etiology has not been clearly established, but collagen abnormalities as seen in keratoconus have been reported. The disease usually is asymptomatic except for the progressive deterioration in uncorrected visual acuity (UCVA) and best spectacle-corrected visual acuity (BSCVA) caused by the irregular astigmatism induced by the corneal ectasia.

Patients with PMD are not good candidates for refractive surgery. Reports show that refractive surgery in these patients and generally in patients with ectatic dystrophies results in poor visual outcomes and progressive corneal ectasia.^{2–4} Several possible alternatives to

manage PMD are reported in the literature, including scleral fitted gas-permeable contact lenses, inferior eccentric penetrating grafts, corneal wedge excision, penetrating keratoplasty (PKP), and deep lamellar keratoplasty.^{5–9}

Intrastromal corneal ring segments (Intacs, Addition Technology, Inc.) were first used in patients with low myopia.¹⁰ Because of the removable and tissue-saving character of this technique, its application could expand to patients with corneal thinning disorders when refractive surgery is not suitable. Several reports demonstrate the efficacy of Intacs in correcting low myopia, and preliminary studies show encouraging results in eyes with post-LASIK corneal ectasia and in keratoconic eyes.^{11–15}

We present Intacs implantation for early PMD in a 42-year-old man.

Case Report

A healthy 42-year-old man was referred to our clinic for the correction of ametropia. His manifest refraction was +3.75 –8.50 × 85 in the right eye and +2.00 –4.50 × 90 in the left eye. The cycloplegic refraction was +4.25 –8.50 × 85 in the right eye and +2.50 –4.25 × 90 in the left eye. The patient was contact-lens intolerant. The

Accepted for publication May 13, 2003.

From the Department of Ophthalmology (Kymionis, Siganos, Pallikaris) and the Vardinoyannion Eye Institute of Crete (Kymionis, Aslanides, Pallikaris), University of Crete, Heraklion, Crete, Greece.

None of the authors has a financial or proprietary interest in any material or method mentioned.

Reprint requests to Dr. George D. Kymionis, Vardinoyannion Eye Institute of Crete, University of Crete, P.O. Box 1352, Heraklion GR-71110, Greece. E-mail: kymionis@med.uoc.gr.

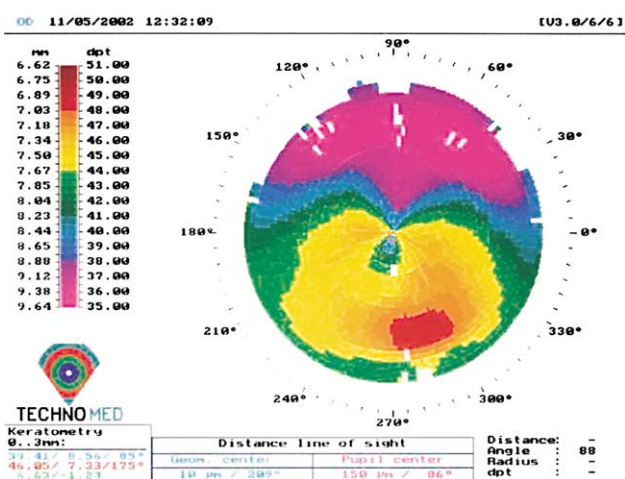
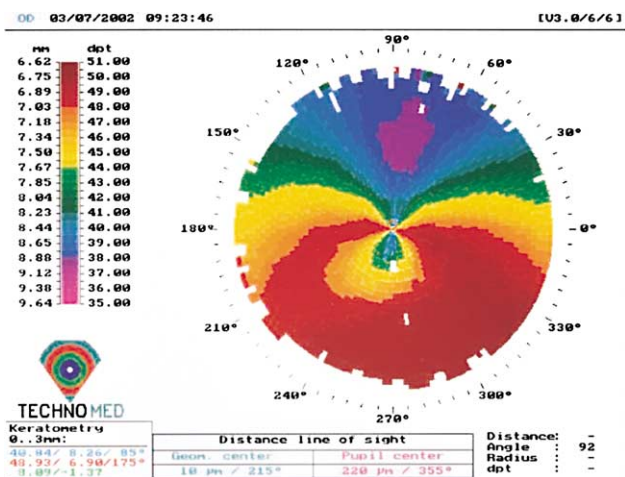


Figure 1. (Kymionis) *Top:* Preoperative topography of a right eye with early PMD. *Bottom:* The eye 11 months after Intacs segment insertion.

UCVA was counting fingers in both eyes, while the BSCVA was 20/50 in the right eye and 20/32 in the left eye. Central corneal pachymetry (ultrasound, Sonogage, DGH 5100 Technology, Inc.) was 550 μm and 560 μm in the right eye and left eye, respectively. Inferior measurements were 530 μm and 550 μm , respectively. Corneal topography (TechnoMed C-Scan, Technomed GmbH) revealed inferior perilimbal steepening in both eyes, more advanced in the right eye, as well as inferior elevation with an area of central corneal flattening (Figure 1, *top*). Corneal slitlamp examination showed no evidence of corneal thinning, iron lines, or protrusion. Posterior segment examination in both eyes was unremarkable. A diagnosis of early PMD was made, and the patient was advised not to have refractive surgery.

After the patient was informed of possible surgical benefits and complications, he was included in a prospective clinical study of the safety and efficacy of Intacs implantation in patients with corneal ectatic dystrophies. The patient gave written informed consent in accordance with the Declaration of Helsinki.

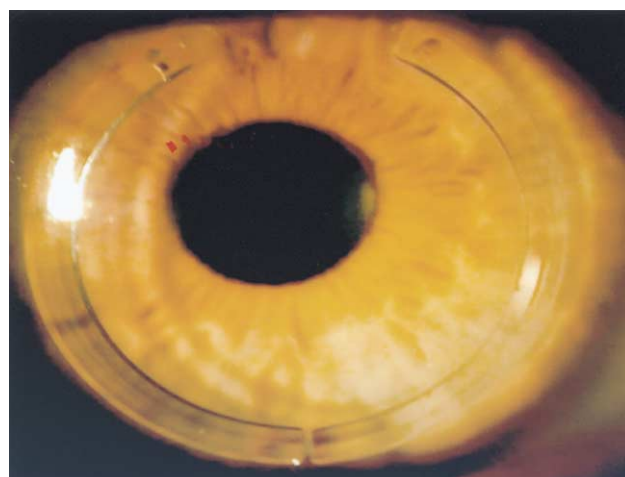


Figure 2. (Kymionis) Slitlamp photograph of the right eye with early PMD after Intacs implantation.

Surgical Procedure

The surgical procedure was performed under topical anesthesia. Two Intacs segments (0.45 mm thickness) were inserted in the fashion typically used for low myopia correction (nasal-temporal). Corneal thickness was measured intraoperatively at the incision site and peripherally in the cornea with ultrasonic pachymetry along the ring placement markings. Using a diamond knife set at 70% of the thinnest corneal measurement (360 μm), a 0.90 mm radial incision was made. Corneal pockets were created using 2 Sinsky hooks and a Suarez spreader. Two corneal tunnels were formed using clockwise and counterclockwise dissectors under suction created by a vacuum-centering guide. The 2 poly(methyl methacrylate) segments were implanted in the respective corneal tunnels to bring them in contact at the inferior ends, aiming for maximal flattening of the inferior cornea (Figure 2). The incision site was closed using a single 10-0 nylon suture. The procedure was uneventful.

Postoperatively, antibiotic-steroid eyedrops 4 times daily for 2 weeks were prescribed. The patient was instructed to avoid rubbing the eye and to use preservative-free artificial tears frequently. The suture was removed 2 weeks after surgery. Eleven months after the procedure, the patient's right eye UCVA was 20/200; BSCVA was 20/25, while manifest refraction was +4.50 -5.50 \times 85 (cycloplegic refraction +5.00 -5.50 \times 85) with an improvement in corneal topographic pattern (Figure 1, *bottom*).

Discussion

Noninflammatory corneal thinning disorders (eg, keratoconus, PMD, and keratoglobus) are characterized by progressive corneal thinning, protrusion, and scarring, which result in visual distortion and reduction.

The origin of these conditions remains unclear and may be associated with a variety of factors.

Pellucid marginal degeneration is an uncommon form of an idiopathic, noninflammatory peripheral corneal thinning disorder. Slitlamp examination is characterized by a peripheral band of thinning of the inferior cornea between the 4 o'clock and 8 o'clock positions. The disease is bilateral but asymmetric in nature. In contrast with peripheral corneal melting disorders (eg, Mooren's ulcer or peripheral melting secondary to rheumatological disorders), the area of thinning typically is epithelialized, clear, avascular, and without lipid deposits.^{1,2}

Spectacle or contact lens correction is beneficial in early stages of the disease. In advanced stages in which spectacles or contact lenses cannot provide visual rehabilitation, invasive therapies may be considered. Standard-sized PKP and alternative techniques have varied results.⁵⁻⁹ Furthermore, the side effects of prolonged use of steroids after keratoplasty dictate the application of surgical treatment only in patients with advanced disease.

In 2002, Colin and coauthors¹¹ published preliminary results of managing keratoconus with Intacs. A year later, they reported on a series of 10 keratoconic patients 1 year after Intacs implantation,¹² demonstrating that Intacs reduced corneal steepening and astigmatism while visual acuity improved in almost all eyes. The surgical procedure was similar to that for low myopia correction except for the Intacs segment thickness and the location of the incision site. In all patients, the authors used a temporal incision; a 0.45 mm thickness segment was inserted inferiorly and a 0.25 mm thickness segment, superiorly to counterbalance and flatten the overall anterior corneal surface.

Recently, we published our experience with Intacs implantation in keratoconic eyes using a different surgical approach. In our study,¹³ 2 Intacs segments of the same thickness (0.45 mm) were inserted in all eyes while their positioning depended on the topographic findings. In this case report, we describe our successful experience with Intacs implantation in a patient with early PMD. There was an improvement in UCVA, BSCVA, and the topographic findings.

Several questions arise from this case report. In advanced stages of the disease, the progressive thinning of the inferior part of the cornea makes implantation

of Intacs, especially the inferior part, technically difficult. To avoid perforation in these cases, a thinner segment (0.25 mm) could be used in the inferior part of the cornea.

Another issue with this technique is the possibility of stabilization and/or elimination of the progression of ectatic disease. Further investigation with more cases and follow-up is necessary. Additionally, the implantation of segments in different sites of the cornea (superior-inferior or temporal-nasal) must be examined to find the best corneal regions for segment implantation.

Intacs seem to offer a minimally invasive alternative treatment for patients with early PMD. Further studies are needed to draw conclusions about the efficacy of this technique in patients with PMD.

References

1. Krachmer JH. Pellucid marginal corneal degeneration. *Arch Ophthalmol* 1978; 96:1217-1221
2. Ambrósio R Jr, Wilson SE. Early pellucid marginal corneal degeneration; case reports of two refractive surgery candidates. *Cornea* 2002; 21:114-117
3. Seiler T, Quorke AW. Iatrogenic keratectasia after LASIK in a case of forme fruste keratoconus. *J Cataract Refract Surg* 1998; 24:1007-1009
4. Schmitt-Bernard C-FM, Lesage C, Arnaud B. Keratectasia induced by laser in situ keratomileusis in keratoconus. *J Refract Surg* 2000; 16:368-370
5. Biswas S, Brahma A, Tromans C, Ridgway A. Management of pellucid marginal corneal degeneration. *Eye* 2000; 14:629-634
6. Rasheed K, Rabinowitz YS. Surgical treatment of advanced pellucid marginal degeneration. *Ophthalmology* 2000; 107:1836-1840
7. Varley GA, Macsai MS, Krachmer JH. The results of penetrating keratoplasty for pellucid marginal corneal degeneration. *Am J Ophthalmol* 1990; 110:149-152
8. MacLean H, Robinson LP, Wechsler AW. Long-term results of corneal wedge excision for pellucid marginal degeneration. *Eye* 1997; 11:613-617
9. Schanzlin DJ, Sarno EM, Robin JB. Crescentic lamellar keratoplasty for pellucid marginal degeneration [letter]. *Am J Ophthalmol* 1983; 96:253-254
10. Holmes-Higgin DK, Burris TE. Corneal surface topography and associated visual performance with INTACS for myopia; phase III clinical trial results; the INTACS Study Group. *Ophthalmology* 2000; 107:2061-2071
11. Colin J, Cochener B, Savary G, Malet F. Correcting keratoconus with intracorneal rings. *J Cataract Refract Surg* 2000; 26:1117-1122

12. Colin J, Cochener B, Savary G, et al. INTACS inserts for treating keratoconus; one-year results. *Ophthalmology* 2001; 108:1409–1414
13. Siganos CS, Kymionis GD, Kartakis N, et al. Management of keratoconus with Intacs. *Am J Ophthalmol* 2003; 135:64–70
14. Siganos CS, Kymionis GD, Astyrakakis N, Pallikaris IG. Management of corneal ectasia after laser in situ keratomileusis with INTACS. *J Refract Surg* 2002; 18:43–46
15. Kymionis GD, Siganos CS, Kounis G, et al. Management of post-LASIK corneal ectasia with Intacs inserts; one-year results. *Arch Ophthalmol* 2003; 121:322–326