

Vardhaman P. Kankariya  
MD

# Corneal Inlays: Resurgence of Intra-Corneal Lenses in Presbyopia Reversal

Vardhaman P. Kankariya MD<sup>1,2,3</sup>, Aliko N. Linnopoulou MD, MSC<sup>2</sup>,  
George D. Kymionis MD, PHD<sup>2</sup>, Sonia H. YOO MD<sup>3</sup>, Ioannis Pallikaris MD<sup>2</sup>

1. Sai Surya Eye Care and LASIK Centre, India; 2. Institute of Vision and Optics, Greece;  
3. Bascom Palmer Eye Institute, USA

The necessity to develop a minimally invasive, safe and potentially reversible technique for the compensation of presbyopia in plano, presbyopic patients aged 45-60 years old, who are considered too old for laser corneal refractive surgery and too young for cataract operation, led to the development of a new modified monovision approach where intracorneal phakic inlays are implanted into an intrastromal corneal pocket in the non-dominant eye of the patient. The intracorneal pocket is either created mechanically with a microkeratome or with the femtosecond laser. Major advantages of the procedure are the easy surgical technique, the potential reversibility and the ability to combine with several surgical corneal and intraocular modalities for the correction of refractive errors and presbyopia<sup>1</sup>.

## Types of Current Corneal Inlays

The current utilized intracorneal inlays for the treatment of presbyopia can be categorized into three groups according to their mechanisms of action:

- 1) Intracorneal inlays that reshape the anterior surface of the cornea, increasing its curvature, making the tissue steeper. Those inlays are made of hydrogel and an example inlay with this mechanism of action is the Vue+ inlay (ReVision).
- 2) Intracorneal inlays made of Polyvinylidene Fluoride (PVDF) that act as small apertures increasing the depth of focus through a pinhole effect. An example inlay with this mechanism of action is the Kamra inlay (AcuFocus).
- 3) Intracorneal inlays made of Hydrophilic Acrylic that serve as a refractive addition lens, creating a bifocal optical system in the patient's cornea. An example

inlay with this mechanism is the Flexivue MicroLens (Presbia, CA, Netherlands).

## History of Intracorneal Lenses

Jose Barraquer in 1949<sup>2</sup> first described the implantation of a synthetic lenticule inside the cornea for the correction of aphakia and high myopia. The technique was known as Synthetic Keratophakia. Those premature intracorneal inlays were composed of glass and plexiglass. These high-index polymers were used due to their optical abilities in order to treat high myopia<sup>3</sup>. Their limited permeability of fluids, nutrients and products of cells' metabolism, led to anterior stromal thinning of the cornea, stromal opacities and keratolysis. In the literature, the results of the experimental use of intracorneal inlays from synthetic polymers as glyceryl methacrylate<sup>4</sup> and later on from

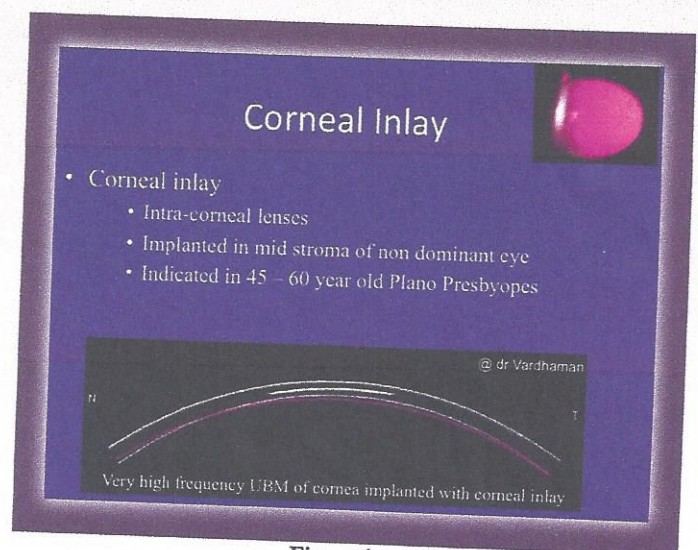


Figure 1



### Modern Corneal Inlays

- Categorized into three groups according to their mechanisms of action:
  - 1) Intracorneal inlays that reshape the anterior surface of the cornea, increasing its curvature, making the tissue steeper. Those inlays are made of hydrogel and an example inlay with this mechanism of action is the Vue+ inlay (ReVision).
  - 2) Intracorneal inlays made of Polyvinylidene Fluoride (PVDF) that act as small apertures increasing the depth of focus through a pinhole effect. An example inlay with this mechanism of action is the Kamra inlay (AcuFocus).
  - 3) Intracorneal inlays made of Hydrophillic Acrylic that serve as a refractive addition lens, creating a bifocal optical system in the patient's cornea. An example inlay with this mechanism is the Flexivue Microlens (Presbia, CA, Netherlands).

Figure 2

### Kamra Inlay (Acufocus)

The diagram illustrates the Kamra inlay's mechanism. It shows a cross-section of the eye with the inlay implanted in the stroma. The inlay has a central opening (pinhole) and an outer annulus. Light rays from a near object pass through the pinhole, creating a clear image on the retina. The diagram also shows the inlay's dimensions: an outer diameter of 3.8mm and a central opening of 1.6mm.

Figure 4

### Modern Corneal Inlays

<b>Kamra (Acufocus)</b> ACUFOCUS	
<b>Presbia Micro-Lens (Flexivue)</b> Presbia	
<b>Presbylens (ReVision)</b> ReVision Optics	

Figure 3

hydrogel<sup>5</sup>, revealed that hydrogel as a material of choice for the creation of intrastromal inlays. It was semi permeable to the fluids and nutrient ingredients for the cornea, but had limited optical properties due to its low optical index of refraction.

The PermaVision Intracorneal Lens (Anamed, Lake Forest, CA) was made from a hydrogel-based material called Nutrapore. It had a diameter ranging between 5.0 to 5.5mm, with central thickness of 30 to 60  $\mu$ m. Its mechanism of action was to alter anterior cornea's surface curvature to treat ametropia and presbyopia by creating a multifocal pattern on the tissue's surface. Similar mechanism of action was recorded for the Intra Lens (Lake Forest, CA) and the current Vue+ inlay (ReVision Optics, Lake Forest, CA).

The Intracorneal Microlens (BioVisionAG, Bruggs, Switzerland) was a lenticule of 3.0mm diameter and 20 $\mu$ m

thickness, made from hydrogel, with an addition refractive power and a central opening permitting flow of fluids and nutrients to the anterior central cornea. This inlay was implanted into a stromal pocket created by a mechanical microkeratome. The Microlens was later named In Vue which represents the former inlay of the Flexivue inlay (Presbia, Amsterdam, Netherlands).

#### Details of Current Designs

Current intracorneal inlays for the compensation of presbyopia in emmetropic, presbyopic patients that are utilized are CE marked and are under the United States Food and Drug Administration (FDA) trial. They consist of the KAMRA inlay (AcuFocus, Irvine, CA), the Vue+ (ReVision Optics, Lake Forest, CA), and the Flexivue Microlens (Presbia, CA, Netherlands).

#### KAMRA inlay by AcuFocus (AcuFocus, Inc. Irvine, CA)

The KAMRA inlay by AcuFocus (AcuFocus, Inc. Irvine, CA) is a small aperture corneal inlay for treatment of presbyopia in emmetropic, presbyopic patients that utilizes the pinhole effect to increase depth of field by selecting for central light rays only. The Kamra inlay has an outer diameter of 3.8mm, a central annulus of 1.6mm that serves as pinhole and 5 $\mu$ m thickness. It is made of bio-compatible polyvinylidene fluoride (PVDF) and is implanted inside a corneal pocket at 200 $\mu$ m stromal depth, created by the femtosecond laser. It also has eight thousand four hundred laser-etched openings of 5.5 to 11.5 $\mu$ m in order to allow the metabolic flow to the anterior cornea, distributed in a designed pseudorandom pattern. Also, a combined implantation of the Kamra inlay with simultaneously performed LASIK to treat ametropia and presbyopia has been described. In that case, the inlay



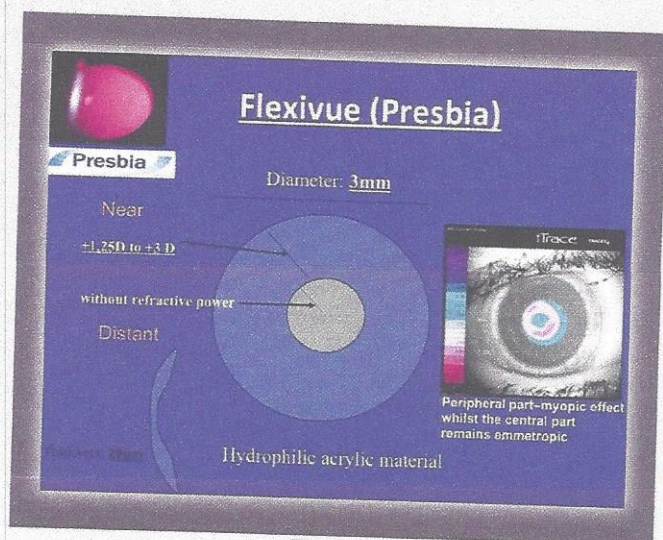


Figure 5

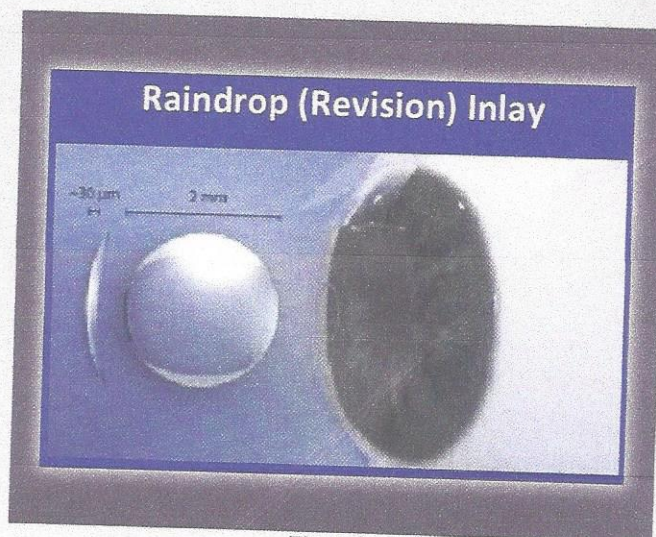


Figure 6

is placed under a corneal flap at  $200\mu\text{m}$  depth after the ablation, in order to relieve the patient from glasses for far and near activities. Examination of ocular structures, diagnostic tests and visual fields measurement are not affected by this procedure.

Seyeddain et al<sup>6</sup> reported two years data on the AcuFocus inlay implanted in 32 eyes and stated that 96.9% of patients could read J3 or better in the operated eye with mean binocular uncorrected near acuity of J1 and mean binocular uncorrected distance visual acuity of 20/16. Yilmaz et al<sup>7</sup> reported 12 months results on 39 presbyopic patients where 12 of them were naturally emmetropic and 27 had emmetropia resulting from earlier LASIK. At one year, the mean uncorrected near visual acuity of the patients participating in the study, improved from J6 preoperatively to J1+. The mean uncorrected distance visual acuity in the operated eyes did not change significantly from preoperatively and remained 20/20 throughout the monitoring period.

#### The Vue+ corneal inlay

The Vue+ corneal inlay, formerly known as the Presbylens (ReVision Optics, Lake Forest, CA) is a permeable hydrogel lenticule with a refractive index similar to the human cornea. The inlay has a diameter of 2mm, is approximately  $10\text{-}\mu\text{m}$  thick at the periphery and has a thickness from 24 to  $40\mu\text{m}$  at the central part. The inlay is inserted under either a LASIK flap or into a corneal pocket at a depth of approximately 120 to  $130\mu\text{m}$  in the non dominant eye of the patients. Its mechanism of action includes alteration of the anterior surface of the corneal curvature, to create a multifocal cornea that improves near and intermediate visual acuity, with slightly affecting distance visual acuity. The constriction of the pupil during near tasks offers an additional pseudo accommodative help. The Vue+ has

received European Conformity (CE) mark in the European Union and has recently completed the first phase of US FDA clinical trials.

Sharma et al<sup>8</sup> reported results on eight emmetropic, presbyopic eyes who underwent implantation of the inlay, under corneal flap created with a microkeratome. All eyes implanted revealed a 20/32 or better unaided near vision, two years postoperatively. All patients recorded that they were satisfied with the outcomes of the procedure and were able to perform typical near activities without glasses. Slade et al presented the six months results of the inlay implantation in natural or post refractive emmetropes, presbyopes at the ASCRS Meeting in 2010<sup>9</sup>. Mean UVA for near was 20/25 and no patient lost two or more lines regarding far vision. Invue lens, (Biovision AG, Brugg, Switzerland) is another corneal inlay which is implanted inside a corneal pocket of the non dominant eye created using a mechanical microkeratome. Bouzoukis et al<sup>10</sup> reported improving visual acuity for near with 20/32 UNVA in 98% of the patients.

#### The Flexivue Microlens (Presbia, Amsterdam, Netherlands) intracorneal inlay

The Flexivue™ Micro-Lens is a transparent, hydrophilic disc with 3 mm diameter and approximately  $15\mu\text{m}$  edge thickness. The central 1.6 mm diameter of the disc is plano and the peripheral zone has an add power. The base power available range from +1.5 D to +3.50 D in 0.25 D increments. At the center of the disc there is a hole of  $0.15\mu\text{m}$  diameter that permits the transfer of oxygen and nutrients of the cornea through the lens. The Microlens is inserted into a stromal pocket created with the femtosecond laser with an insertion device into the non dominant eye concentric with the estimated line of sight.



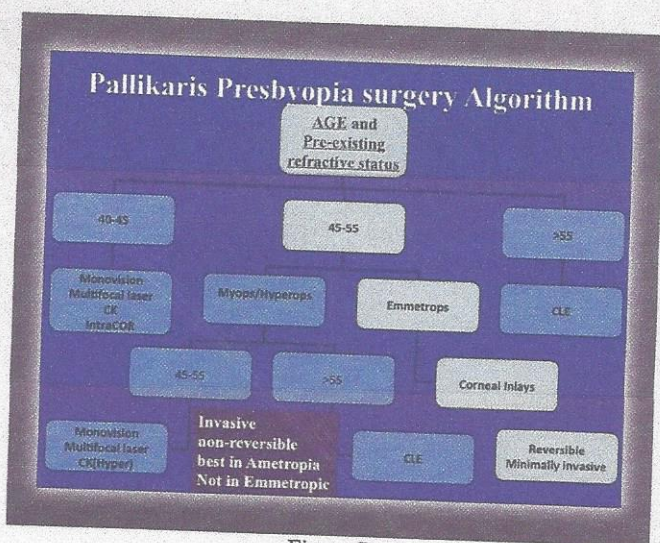

Figure 7

The lens has a bifocal optical system which acts as a modified monovision (smart monovision). During far vision the rays pass through the central zone of the inlay without refractive effect and will be sharply focused on the retina, whereas the rays which pass through the refractive peripheral zone will be not of focus in front of the retina. During near vision, the rays which pass through the central zone will be out of focus behind the retina and the rays which pass through the lens peripheral refractive zone will be focused on the retina. As a result, only the peripheral zone of the lens provides the near vision correction, and affects far vision, whereas the central zone of the lens and the peripheral unaltered part of the cornea do not affect the far vision.

In a study of 43 patients (average age, 52 y) with a mean preoperative UCDA of 20/20 and mean UCNA of 20/50, all patients had an increase in the uncorrected near visual acuity after 1 week. By 1 year, 93% of patients had an UCNA of J2 or better (Limnopoulou, Pallikaris et al, 2012).

**Indication**

Corneal inlays are procedure of choice for Plano presbyopic patients. These group of patients can be 1. Natural planopresbyopes 2. Post LASIK planopresbyopes 3. Post cataract surgery Plano presbyopes. It can also be implanted in ametropic presbyopic patients by performing excimer laser ablation and corneal inlay in the same sitting, either both under the flap or the inlay is implanted in the deep pocket.

**Pre-Operative Work Up**

All patients must undergo an extensive pre-operative work up similar to any refractive surgery patients, including vision (unaided distant and near), manifest refraction (distant and near), IOP, Corneal and anterior segment *biomicroscopy*, *Retinal evaluation*. Ancillary investigations

such as Corneal topography and tomography are must to rule out corneal astigmatism. As all of them have a modified monovision approach, determination of ocular dominance by preferential looking test is a must and usually we give them a contact lens trial of monovision, to know their acceptance.

**Surgical Technique**

Intracorneal inlays may be implanted inside a corneal stromal pocket or under a lamellar corneal flap. The implantation of the intracorneal inlay inside a corneal pocket, provides several advantages. The majority of peripheral corneal nerves are preserved, resulting in unaffected corneal sensitivity and potentially faster visual recovery of the patients. Pocket procedures also allow the preservation of the biomechanical properties of the cornea, offering stable mechanical stability of the tissue. Additionally complications concerning corneal flap creation as striae and free cap are avoided. On the contrary, the creation of a corneal flap permits simultaneous ablation of the stromal tissue with the excimer laser, in order to treat refractive errors along with presbyopia. Also, a corneal flap, allows easy manipulations during a potential reposition or removal of the inlay. It is important to mention that since proper centration of an intracorneal inlay to treat presbyopia is vital for its better performance, a main difference from the standard procedure of creating a LASIK flap, is that an irrigation of the stromal bed is avoided prior to the flap repositioning, in order to inhibit a potential replacement of the lenticule.

During the last decade, in the field of refractive surgery there has been an increasing interest in the use of corneal inlays for the treatment of presbyopia by either using flaps, created by mechanical microkeratomes<sup>11,12</sup> or femtosecond lasers<sup>13</sup>, or by using pockets created by mechanical microkeratomes or femtosecond lasers<sup>14</sup>. Compared to the mechanical technique, the femtosecond laser makes tunnel creation faster, easier and more reproducible as well as offering precise tunnel dimensions (width, diameter and depth) compared to manual techniques, helping in better centration of inlay. This could enhance the predictability, resulting in better final outcomes and improving the safety of the procedure. The development of special softwares for customized pockets has further simplified and increased the efficacy of the procedure.

An additional advantage of the procedure is that is not needed to change or to add new equipment in a modern refractive surgery center, except the special injector and the mask, offering also one more application in the femtosecond laser treatments. The inlays are implanted only in non dominant eye and centration is most crucial. I prefer to center them on excimer laser microscope and ask the patients to focus at the focusing light, so as to know the line of sight. And the inlay is implanted and centered on line of sight. Acutarget



is a sophisticated instruments to identify the line of sight and is provided with AcufocusKamra Inlays.

### Complications of Intracorneal Inlays

Complications regarding the biocompatibility of the material used for the intracorneal lenses have been described and include corneal stromal opacity, haze variants, epithelial or extracellular matrix deposits, infiltration, and keratolysis<sup>15-17</sup>. Modifications of the material in order to be more permeable of fluids and nutrients along with byproducts of the metabolism of the tissue, along with alterations in postoperative medical treatment of the patients to include steroids and occasionally cyclosporine, have assisted in decreasing the appearance of such adverse events and in increasing the tolerance and stability of the outcomes. Additionally, the development of the femtosecond lasers for the creation of the corneal tunnel has increased the predictability, speed and safety of the procedure. The inlays are intolerant to de-centration and need to be re-centered if they move. If the patient has constant glare and optical phenomena, the inlay can be easily removed by opening the pocket.

### Conclusions

Modern Corneal Inlays demonstrate good efficacy of gain in unaided near vision with minimal compromise on unaided distant vision. This minimally invasive and reversible procedure demonstrates good safety and maintenance of corneal structural health. However, new technology merits further long term studies.

### References

1. Kymionis GD, Bouzoukis DI, Pallikaris IG. Corneal inlays: A surgical correction of presbyopia. *J Cat Refr Surg Today Europe* 2007; 3: 48-50.
2. Barraquer J. *Queratoplastica Refractiva. Estudios e informaciones. Oftalmologicas.* 1949; 2: 10.
3. Choyce P. The present status of intracorneal implants. *J Cataract Ophthalmol.* 1968; 3: 295.
4. Dohlman C, Refojo M, Rose J. Synthetic polymers in corneal surgery: glyceryl methacrylate. *Arch. Ophthalmol.* 1967; 177: 52-58.
5. Klyce S, Dingeldein S, Bonanno J, et al. Hydrogel implants: evaluation of first human trial. *Invest. Ophthalmol Vis Sci Suppl.* 1988; 29:393.
6. Seyeddain O, Riha W, Hohensinn M, et al. Refractive surgical correction of presbyopia with the acufocus small aperture corneal inlay: two-year follow up. *J Refract Surg.* 2010; 26: 1-9.
7. Yilmaz O, Bayraktar S, Agca A, et al. Intracorneal inlay for the surgical correction of presbyopia. *J Cataract Refract Surg.* 2008; 34: 1921-27.
8. Sharma G, Porter T, Holliday K, et al. Sustainability and biocompatibility of the Presby-Lens corneal inlay for the correction of presbyopia. *ARVO.* 2010; 51: 813.
9. Slade St. Early results using the presbylens corneal inlay to improve near and intermediate vision in emmetropic presbyopes. Paper presented at the ESCRS annual meeting. September 2010, Paris.
10. Bouzoukis DI, Kymionis GD, Panagopoulou SI, Diakonis VF, Pallikaris AI, Limnopoulou AN, Portaliou DM, Pallikaris IG. Visual outcomes and safety of a small diameter intrastromal refractive inlay

for the corneal compensation of presbyopia. *J Refract Surg.* 2012 Mar;28(3):168-73.

11. Yilmaz OF, Bayraktar S, Agca A, Yilmaz B, McDonald MB, van de Pol C. Intracorneal inlay for the surgical correction of presbyopia. *J Cataract Refract Surg* 2008; 34: 1921-27
12. Mulet ME, Alio JL, Knorz MC. Hydrogel intracorneal inlays for the correction of hyperopia: outcomes and complications after 5 years of follow-up. *Ophthalmology* 2009; 116(8): 1455-66
13. Verity SM, McCulley JP, Bowman RW, Cavanagh HD, Petroll WM. Outcomes of PermaVision intracorneal implants for the correction of hyperopia. *Am J Ophthalmology* 2009; 147(6): 973-7.
14. Bouzoukis D., Kymionis G., Limnopoulou A., Kounis G., Pallikaris I. Femtosecond laser-assisted corneal pocket creation using a mask for inlay implantation. *J Refract Surg* 2011, 20 (10).
15. Barraquer JI. Modification of refraction by means of intracorneal inclusions. *Int Ophthalmol Clin.* 1966;6:53-78.
16. Werblin TP, Patel AS, Barraquer JI. Initial human experience with Permalens myopic hydrogel intracorneal lens implants. *Refract Corneal Surg.* 1992;8:23-26.
17. Alio' JL, Mulet ME, Zapata LF, et al. Intracorneal inlay complicated by intrastromal epithelial opacification. *Arch Ophthalmol.* 2004;122:1441-1446.



Dr. Kapur's  
**THE HEALING TOUCH**  
EYE CENTRE

**D-8, Vikas Puri, New Delhi - 110018**

**Phone No's: 011-28537777, 45623722**

**E-Mail: thehealingtouch2006@rediffmail.com**

## Required

- Ophthalmologist (MD/MS/DO/DNS) (Full Time)  
Specialised in Ant. Segment Diagnosis + OPD Managements. Also trained in Cataract Surgery (Phaco/SICS)
  - Specialist in Retina/Squint/Glaucoma/Corneal Oculoplasty – on Full Time/ Full Time.
- Apply stating expertise and experience.

## REMUNERATION

Commensurate with qualification & experience, negotiable.

Post your CV to [dr.piyushkapur@gmail.com](mailto:dr.piyushkapur@gmail.com). or [mohit.arora247@gmail.com](mailto:mohit.arora247@gmail.com) with in 15 days. You may also contact Mr. Mohit Arora @ 9871789999.